

# Cardiac MR and CT lecture

Copyright (c) 2006 Tóth Attila.

Permission is granted to copy, distribute and/or modify this document under the terms of the Open Publication License, Version 1.0

# Technical challenges

- Cardiac movements
- Respiratory motion
- Spatial resolution
- Temporal resolution

# Cardiac MR technical

- Respiratory cycle
  - Averaging
  - Respiratory compensation
  - Breathholding
  - Navigator echo
  - Real-time imaging
- Cardiac cycle
  - Pulse wave detection
  - ECG sync.
  - Vector ECG (VCG)
  - Self gating
  - Real-time imaging

# Cardiac MR technical

- Spatial and temporal resolution
  - Rapid sequences
    - FSE
    - EPI
    - GRE
    - Hybrid GRE-EPI
      - perfusion
    - **b-SSFP**
      - widely used
- Readout strategy
  - Cartesian (regular)
  - Partial Fourier
  - EPI
  - Spiral
  - Radial

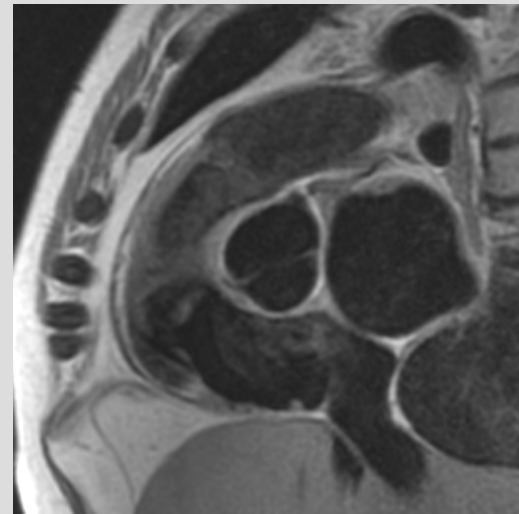
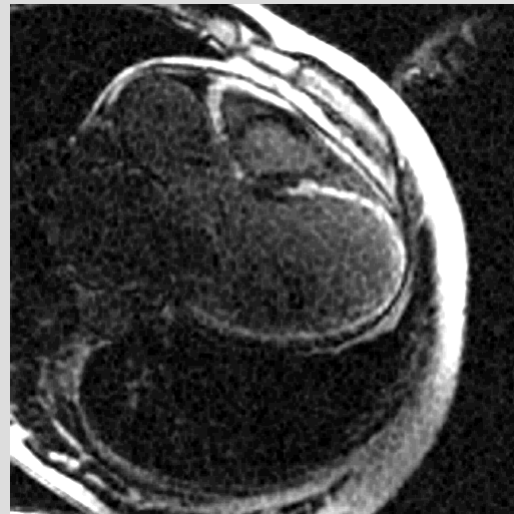
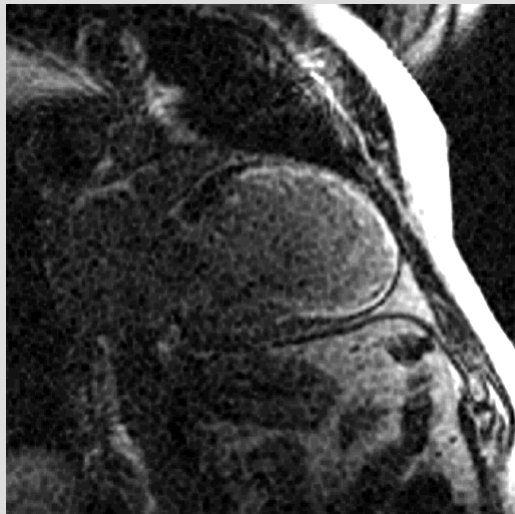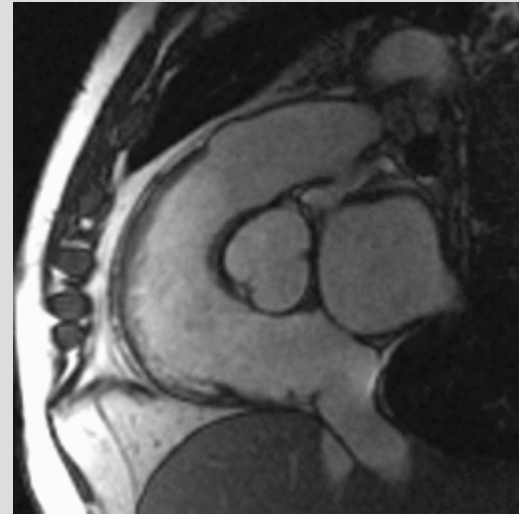
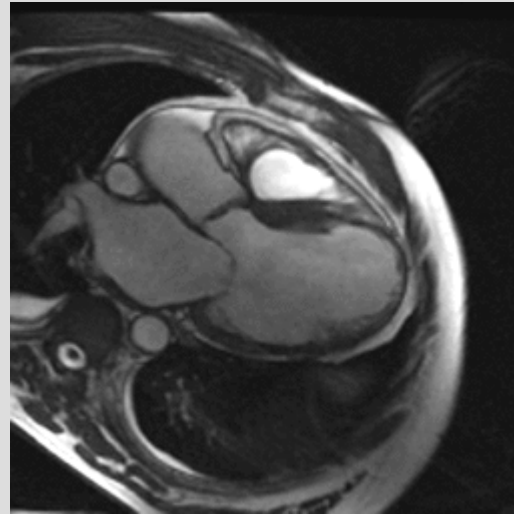
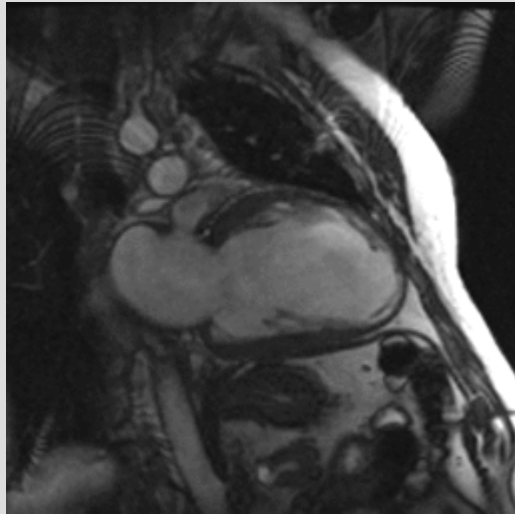
# Cardiac MR technical

- Preparations
  - Blood suppression
  - Fat suppression
  - Saturation
  - Inversion
    - Late enhancement
    - STIR
  - T2-preparation
- Special orientations
  - Axial: transversal
  - 2-chamber, 4-chamber view
  - Left/right ventricular outflow tract
  - Long/short axis slices

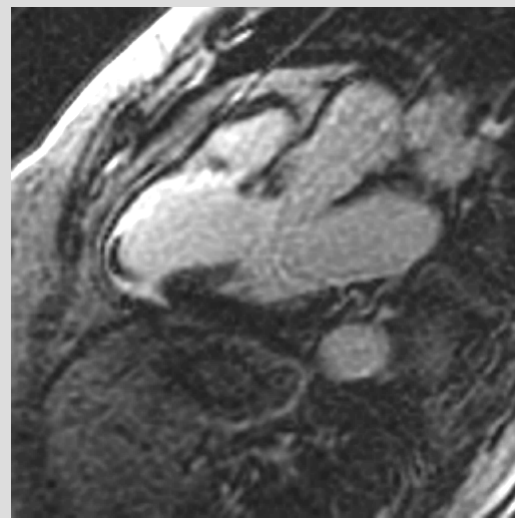
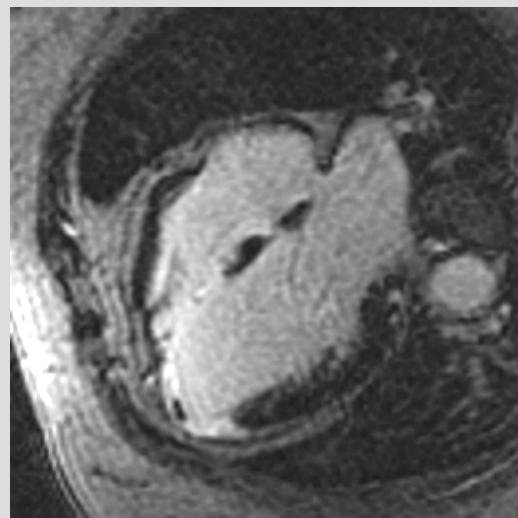
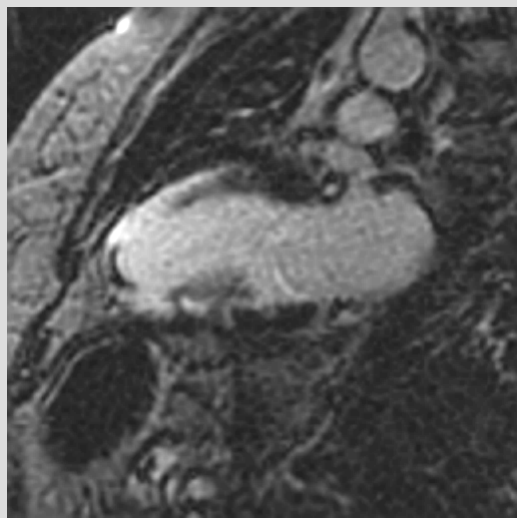
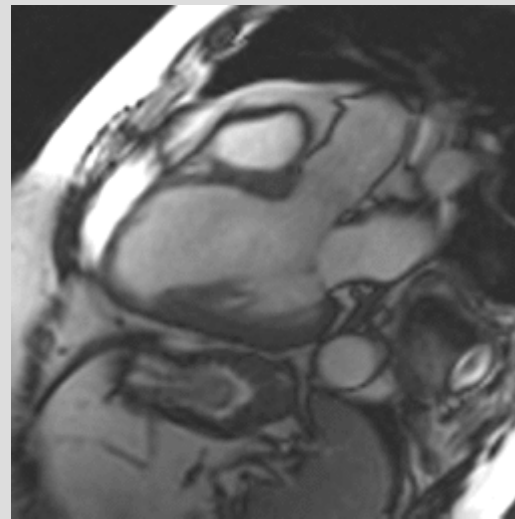
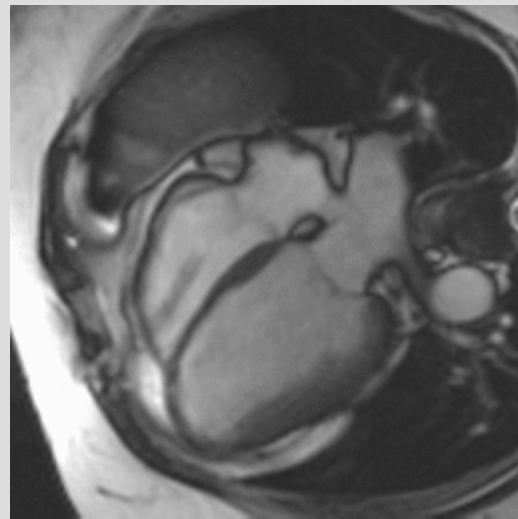
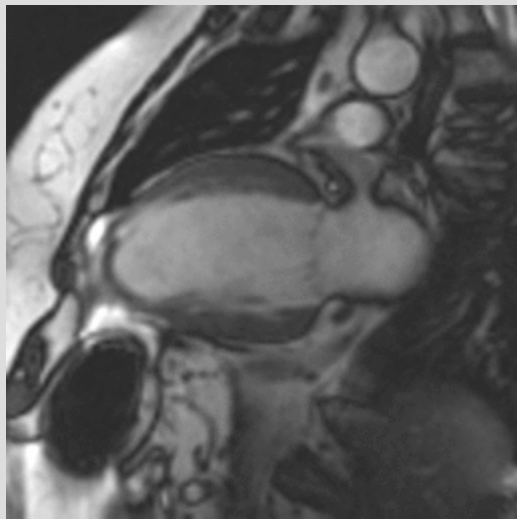
# Indications for referral

- Ischaemic heart disease
- Cardiomyopathies
- Developmental anomalies
- Arrhythmies
- Infectious diseases
- Tumors
- Pericardial diseases
- Cardiac valve abnormalities
- Unanswered question

# Viability

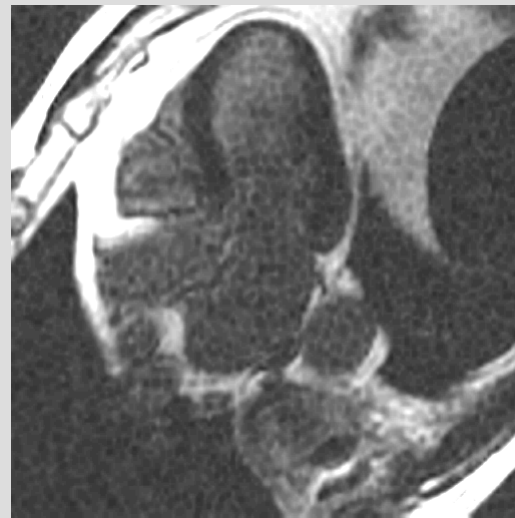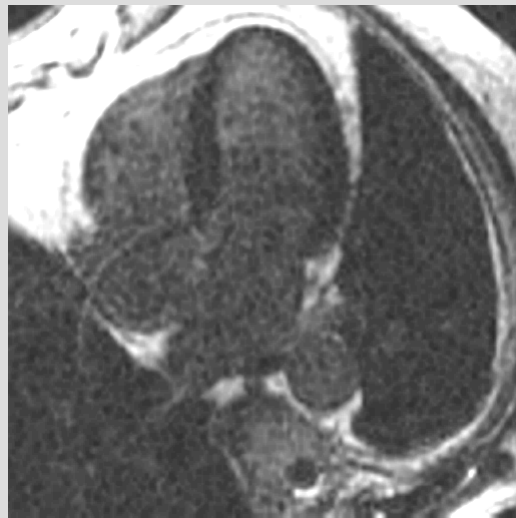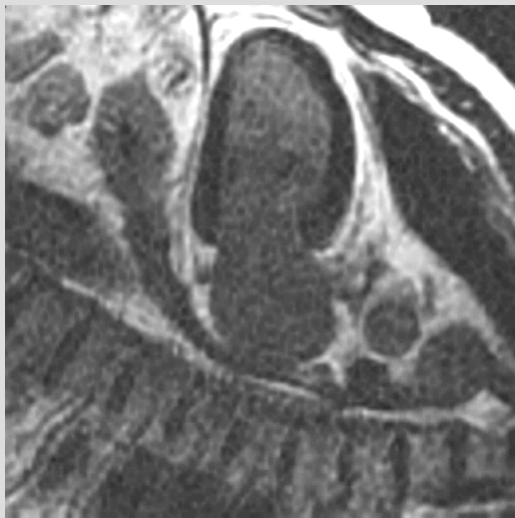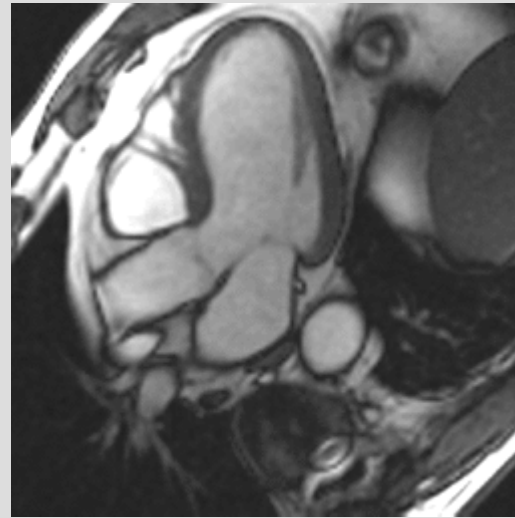
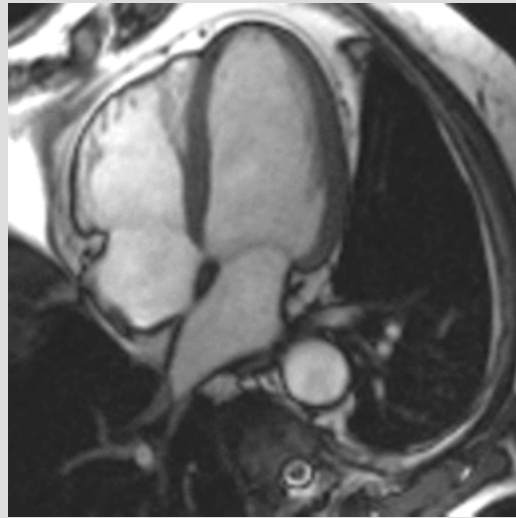
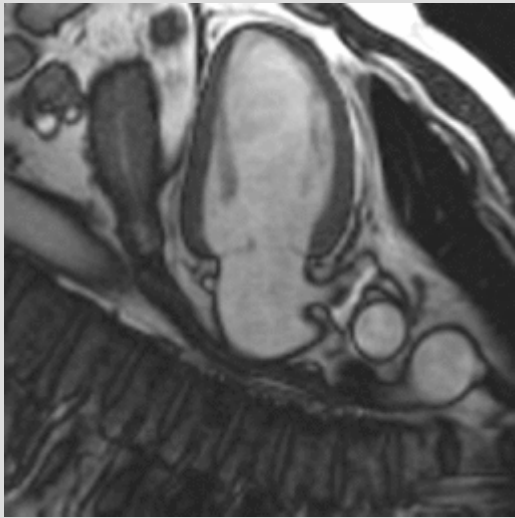


# Non-viable, thrombus

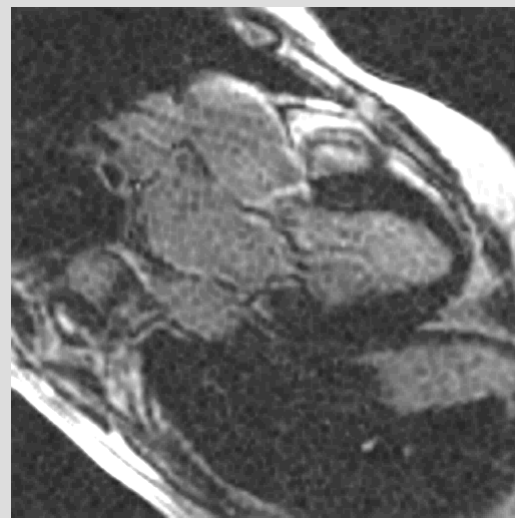
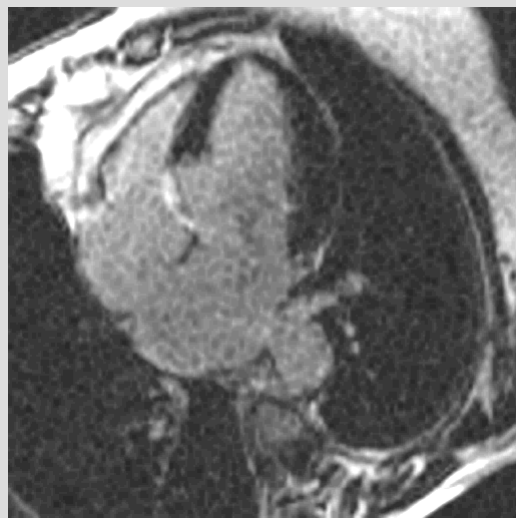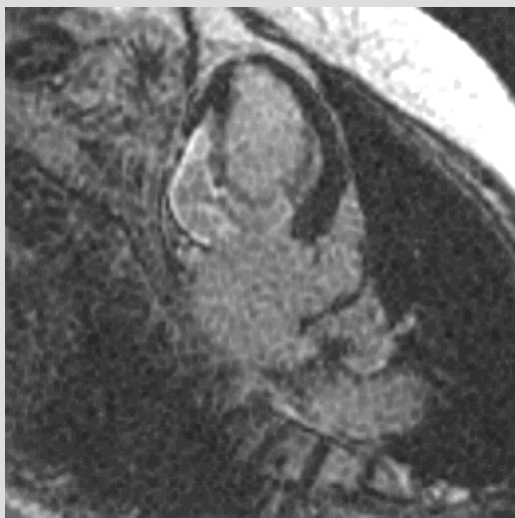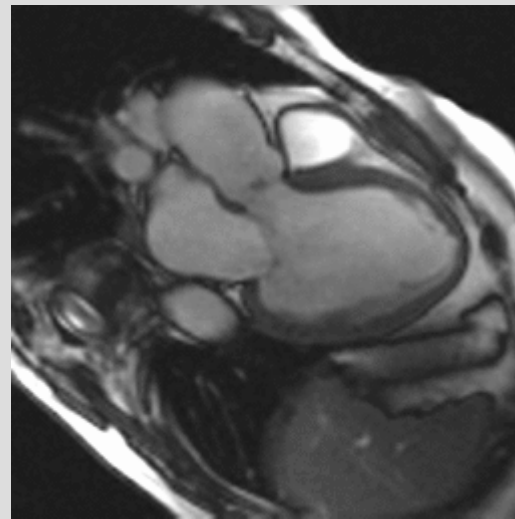
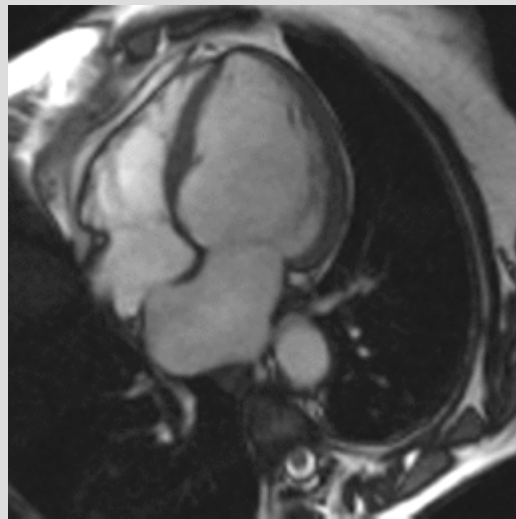
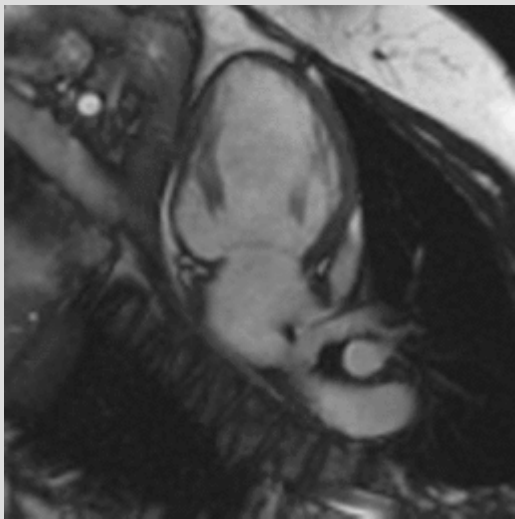




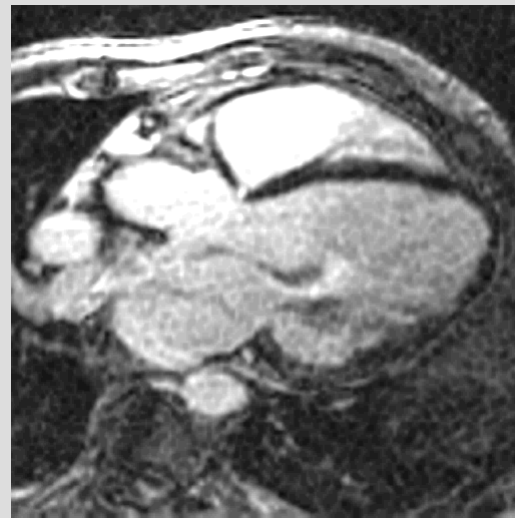
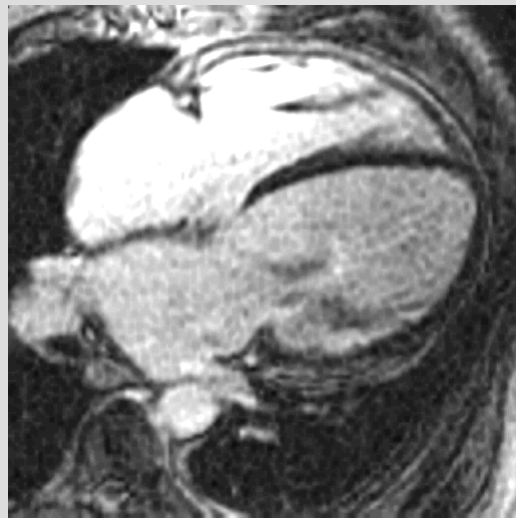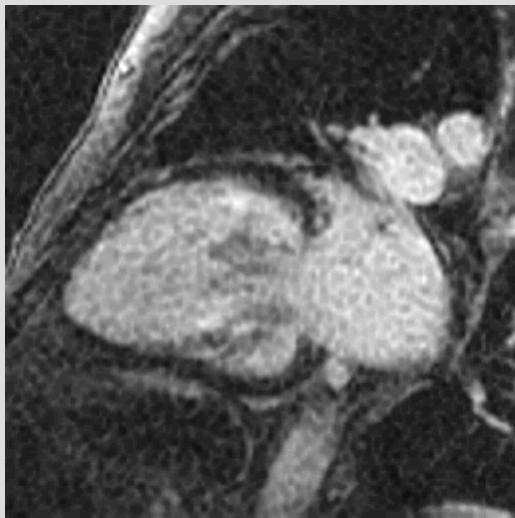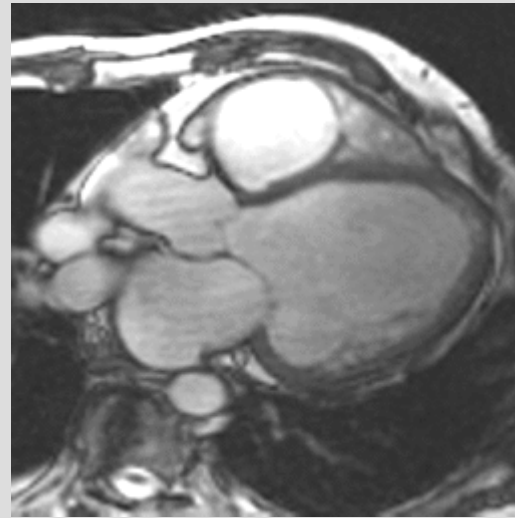
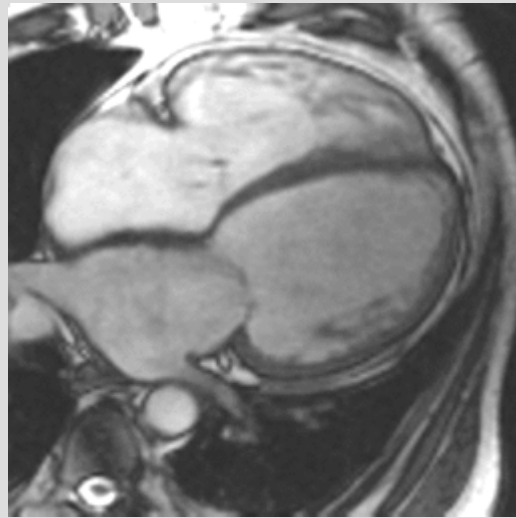
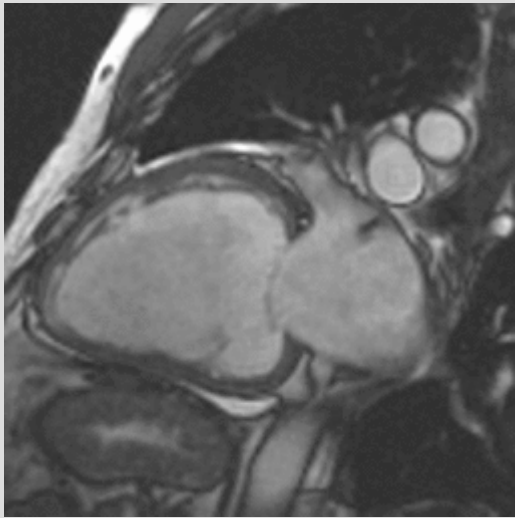
# Viabile



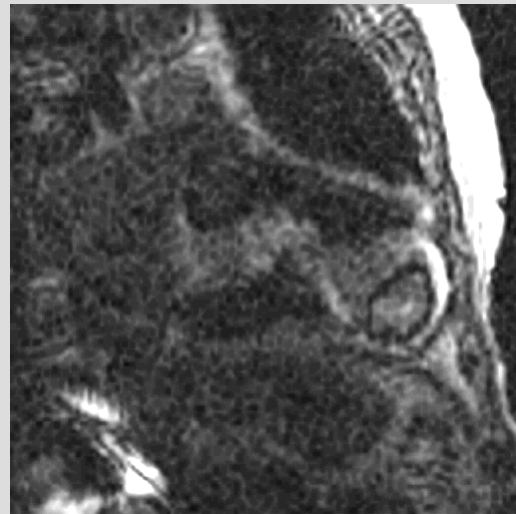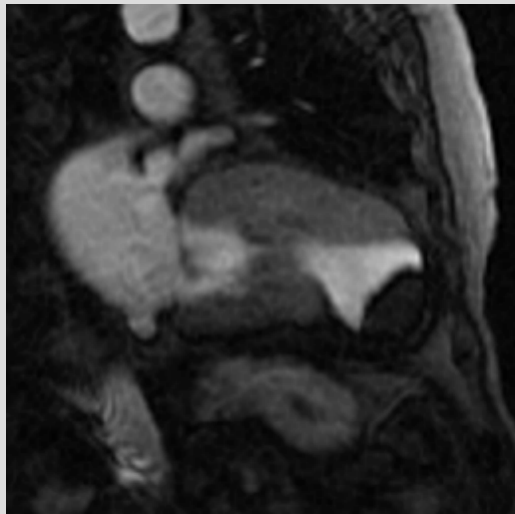
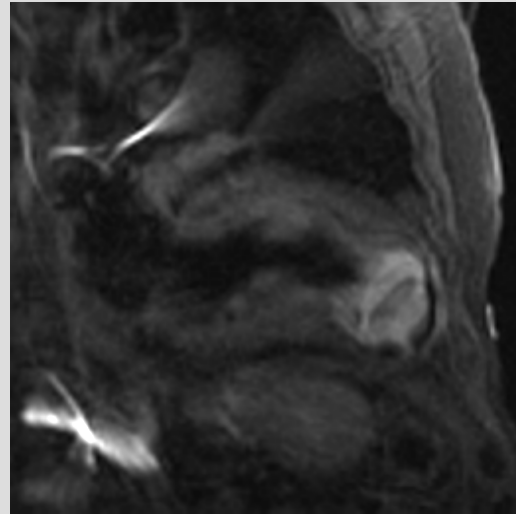
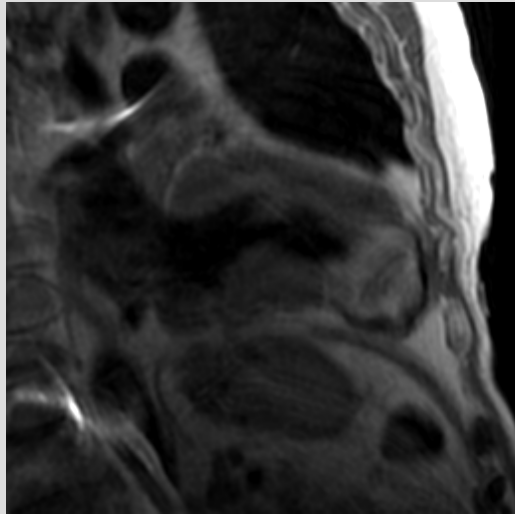
# Worse case



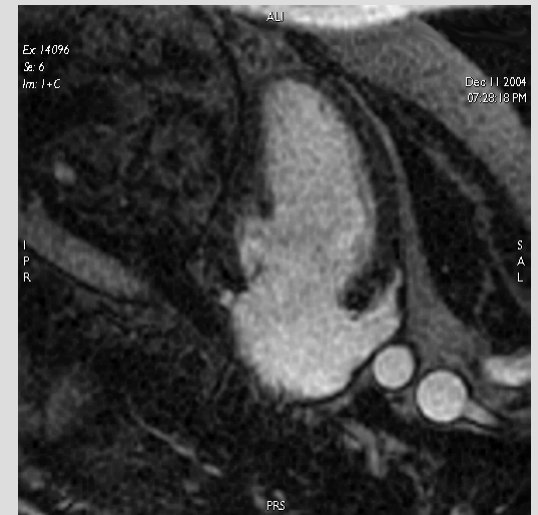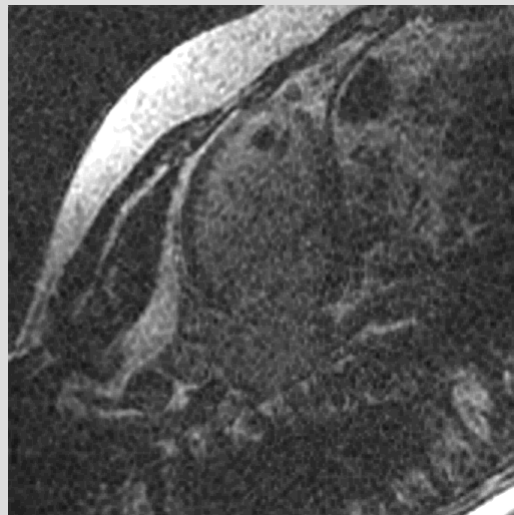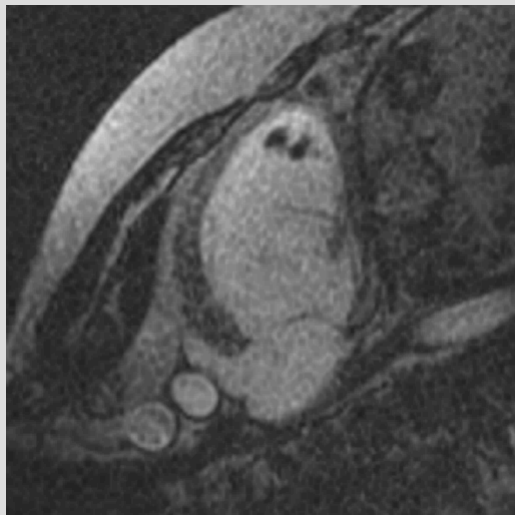
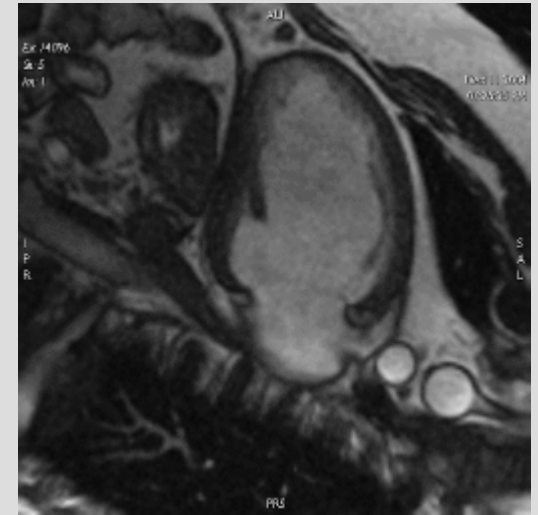
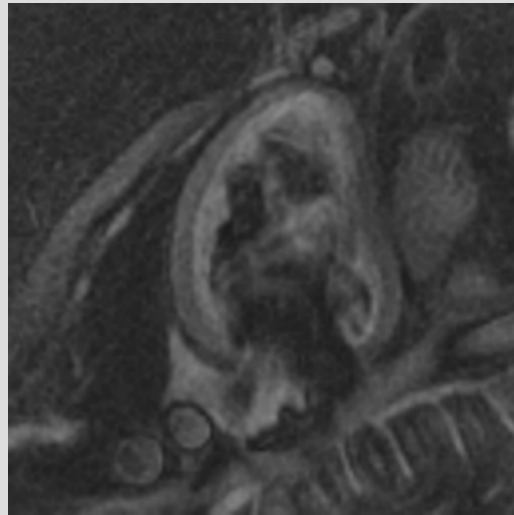
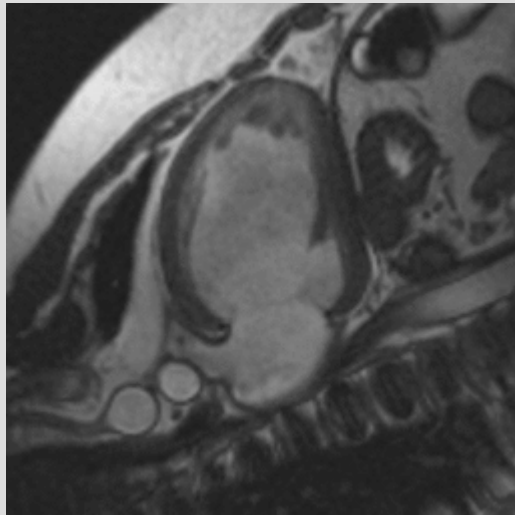
# DCM



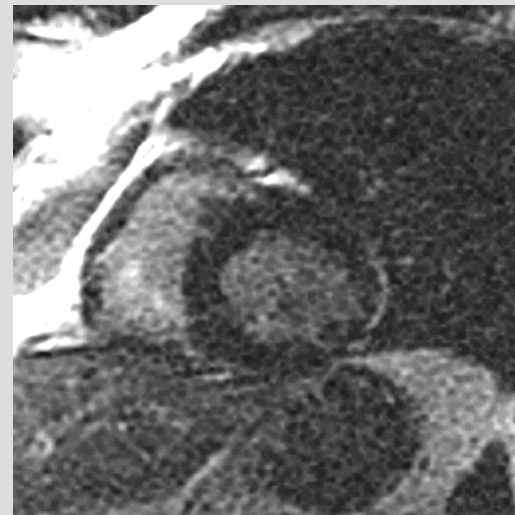
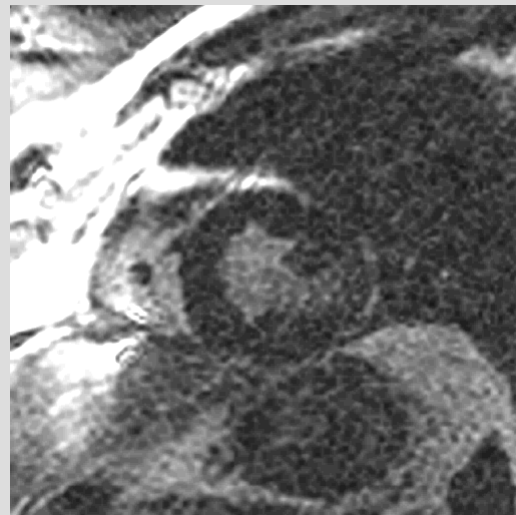
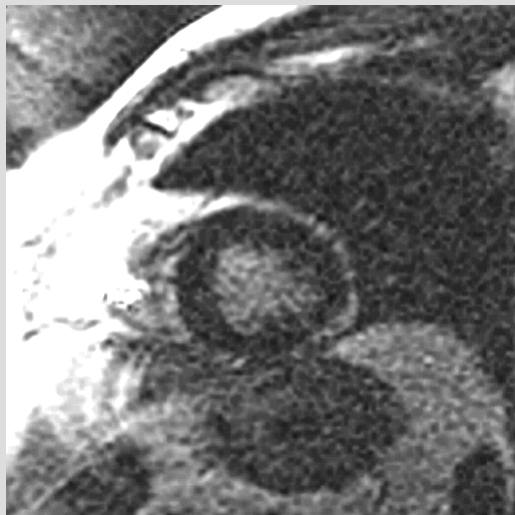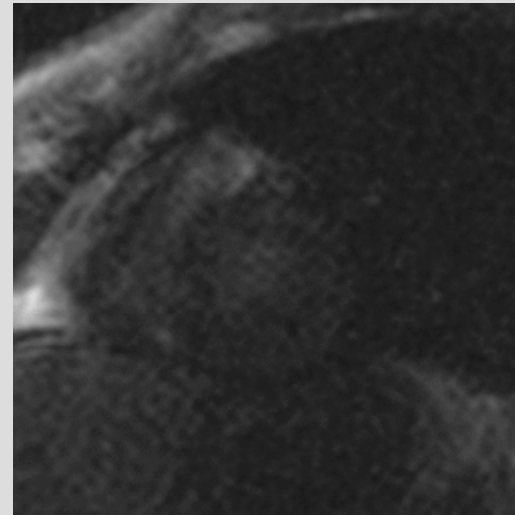
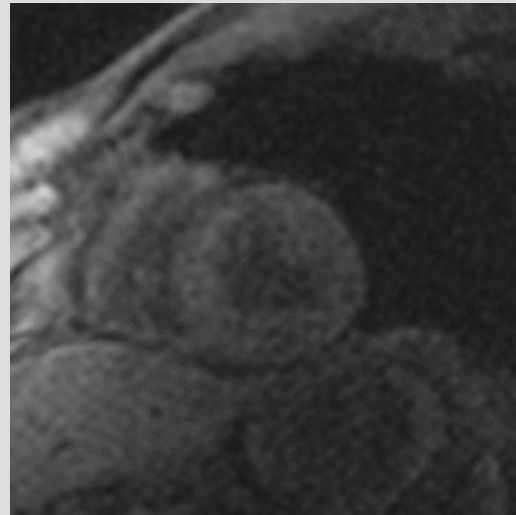
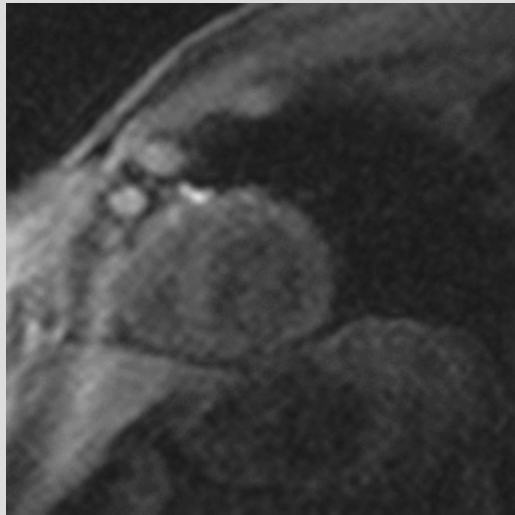
# Calcified apical aneurysm with thrombus



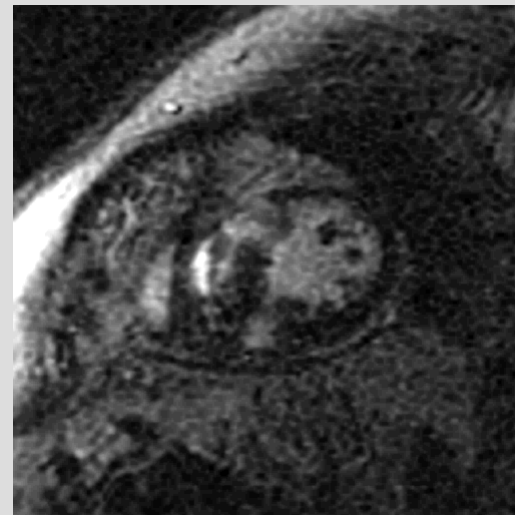
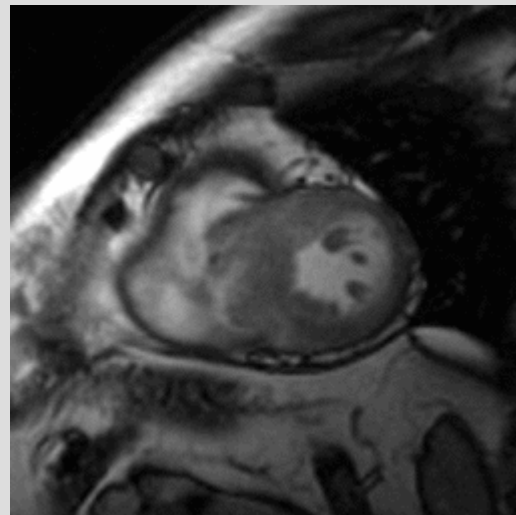
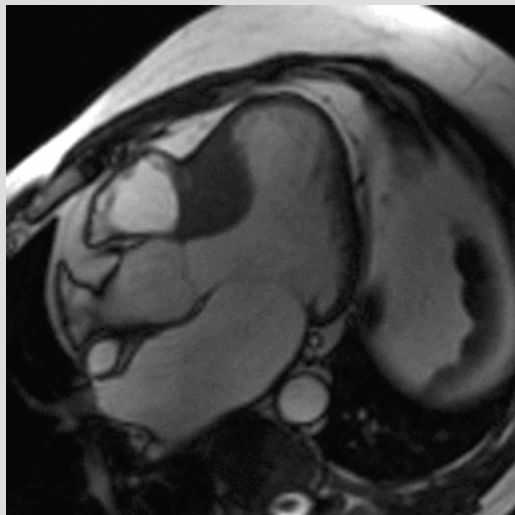
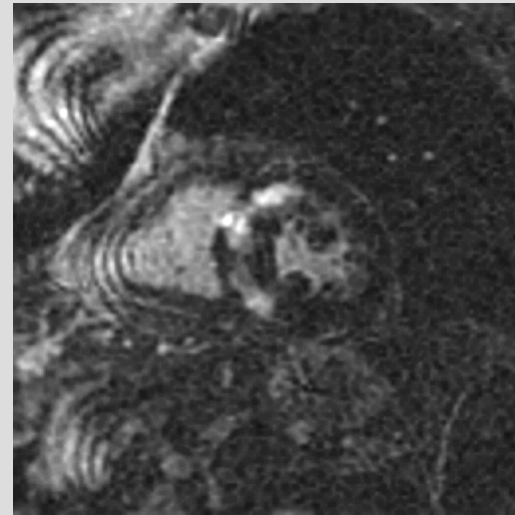
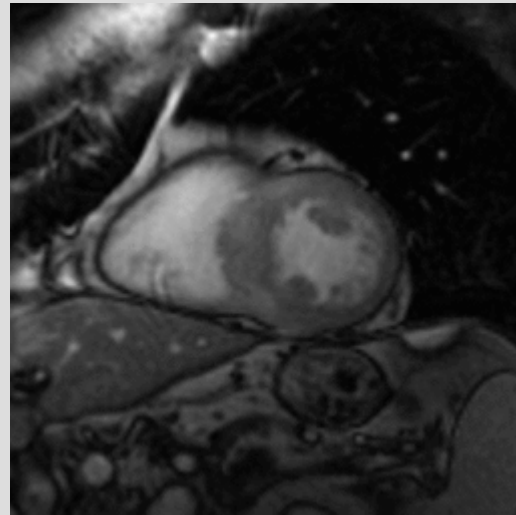
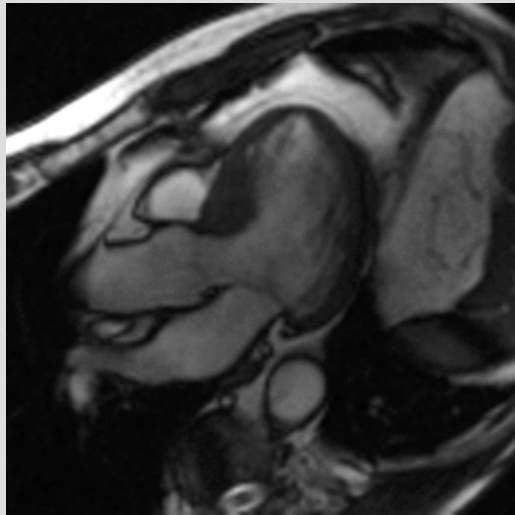
# DCM, apical thrombus



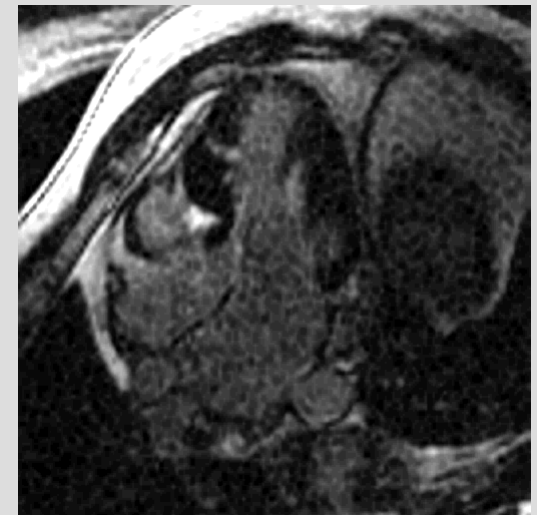
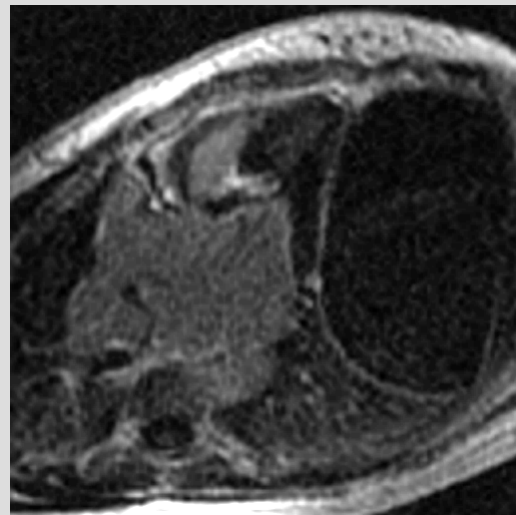
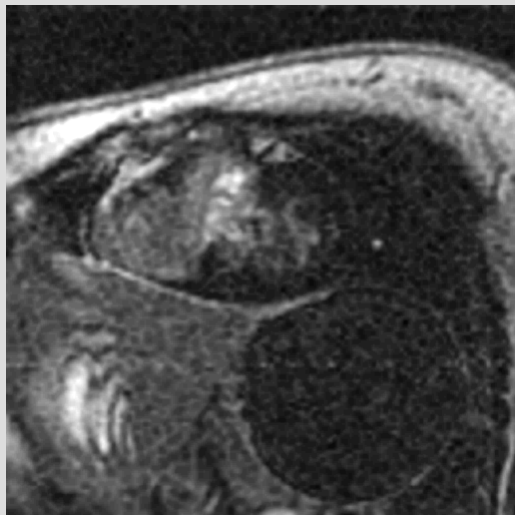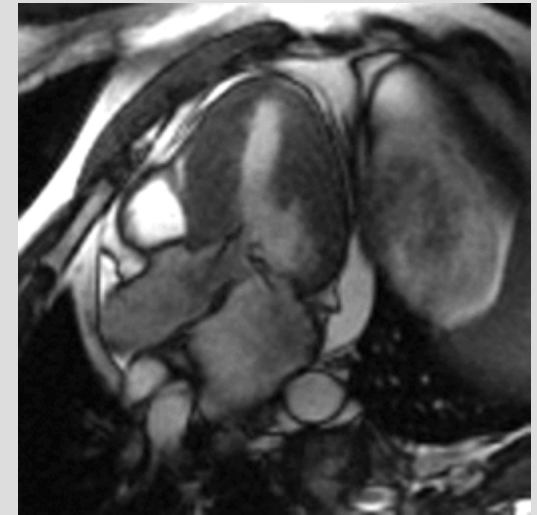
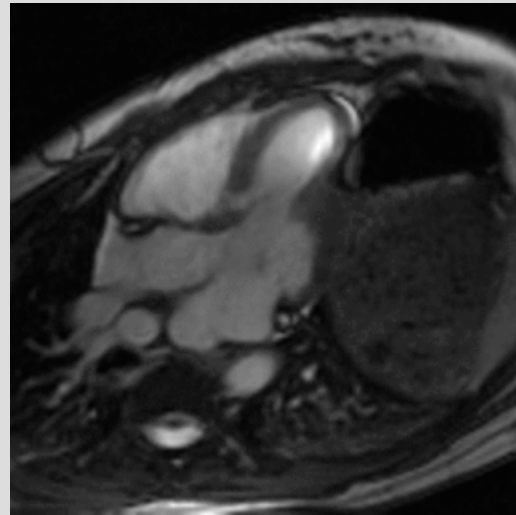
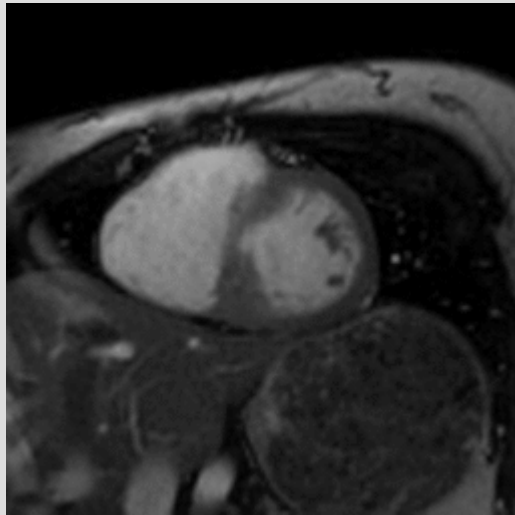
# Stress perfusion



# HCM: LVOT and SA

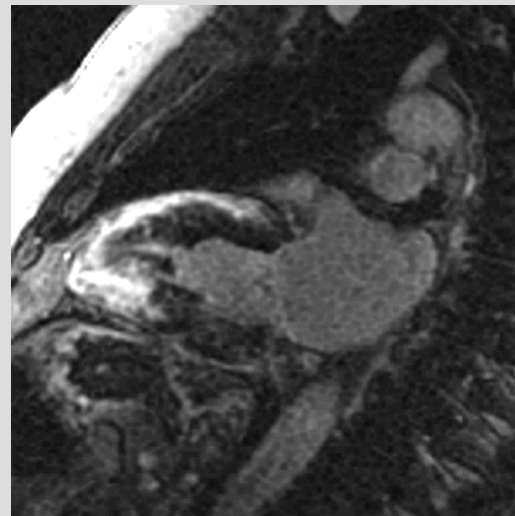
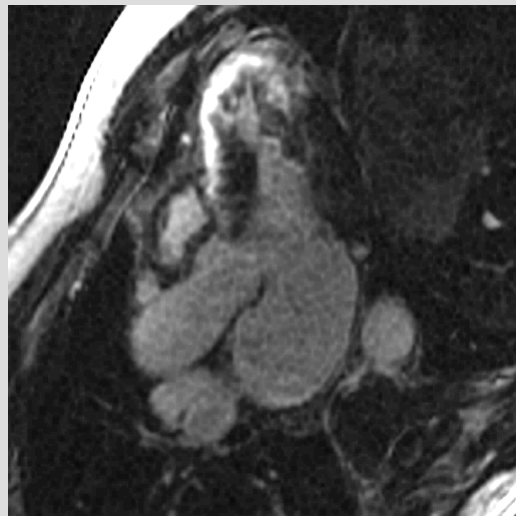
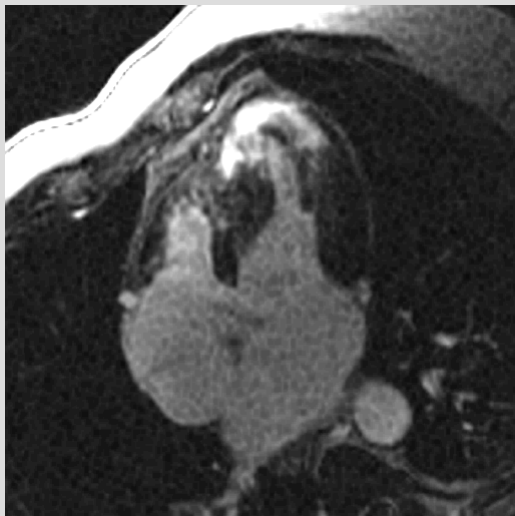
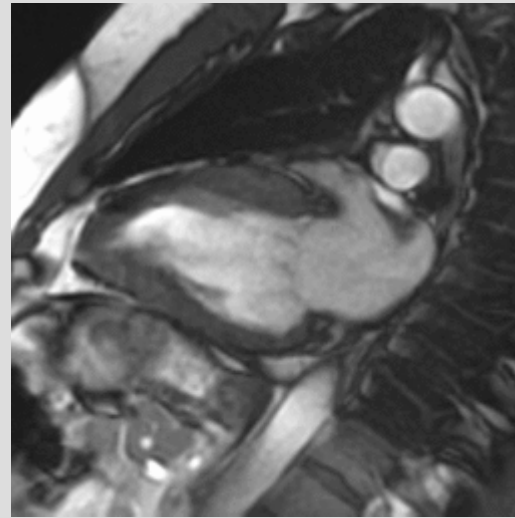
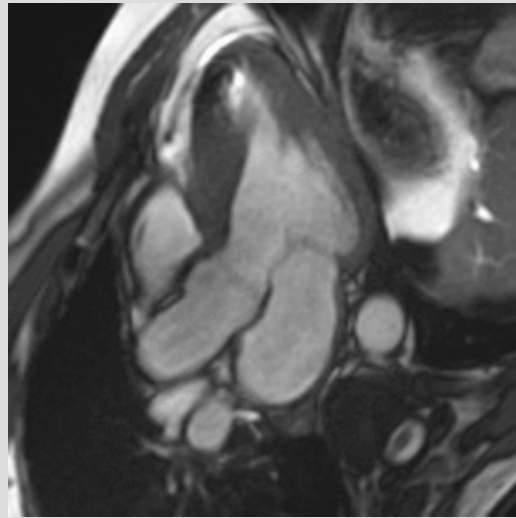
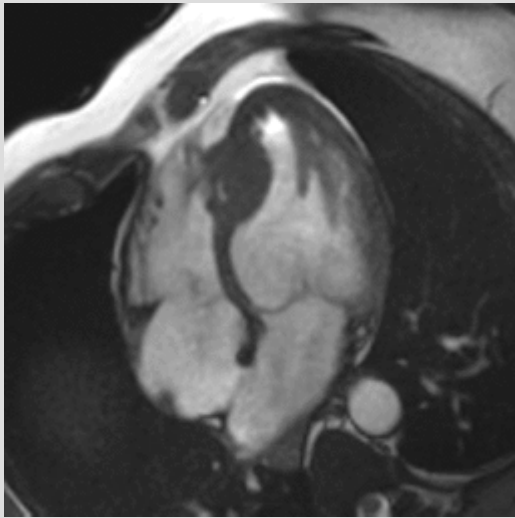


# HCM: st.p.PTSMA, SAM

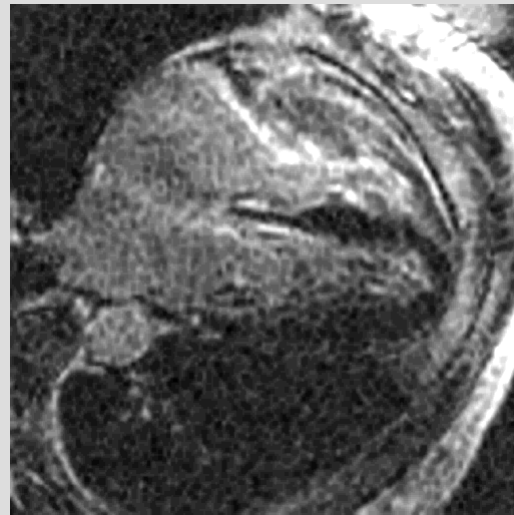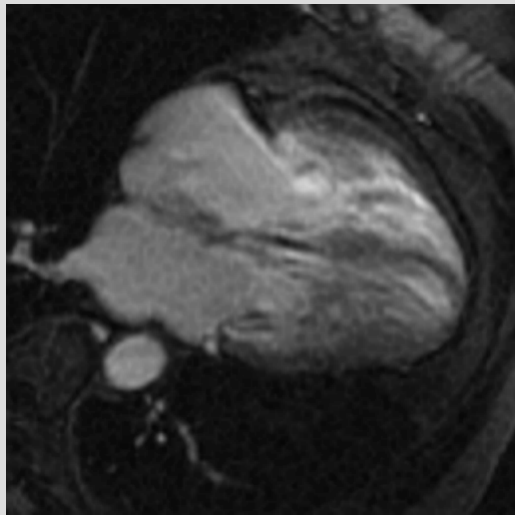
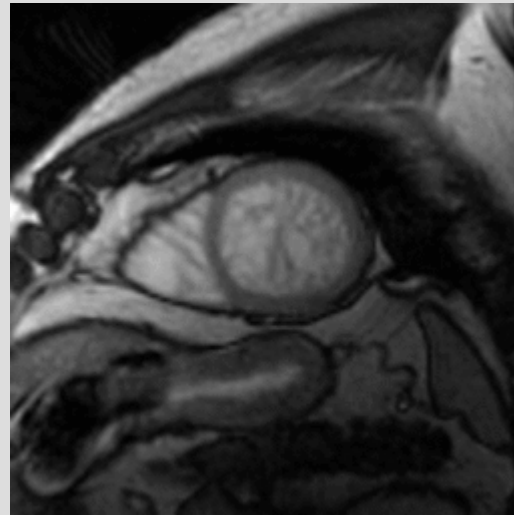
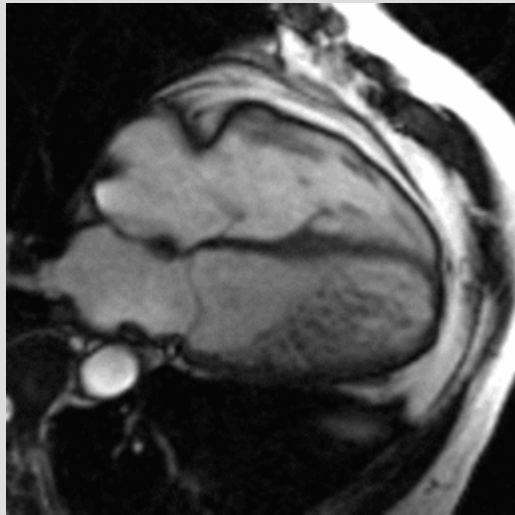




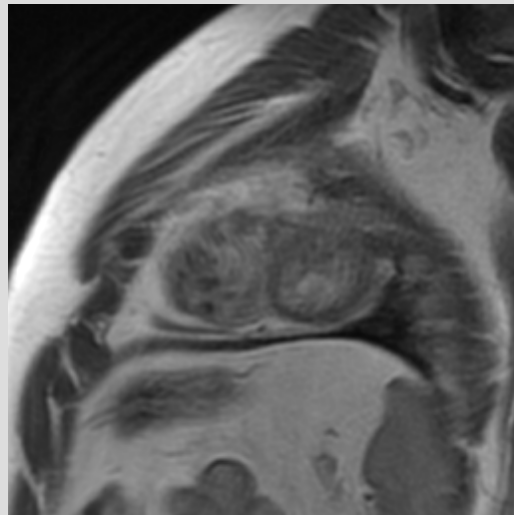
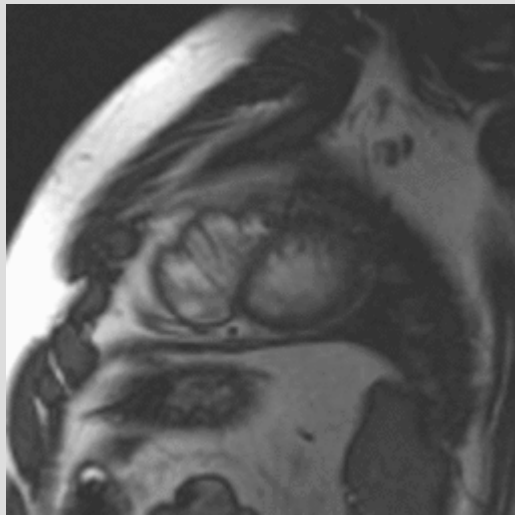
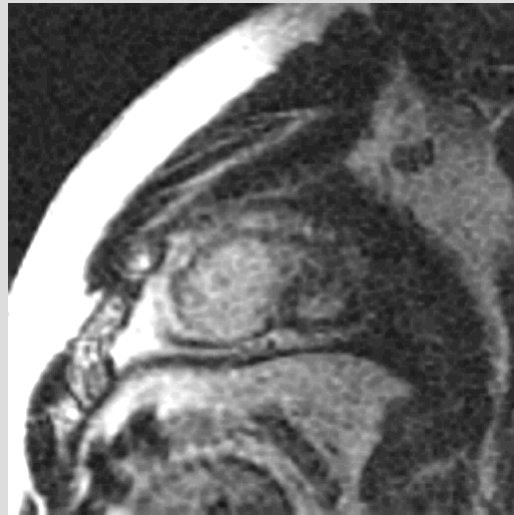
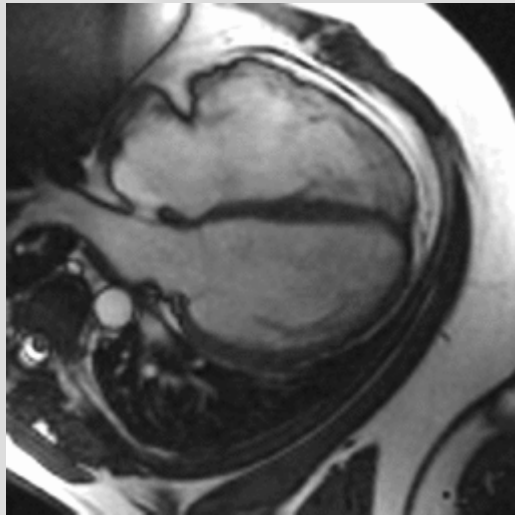
# HCM



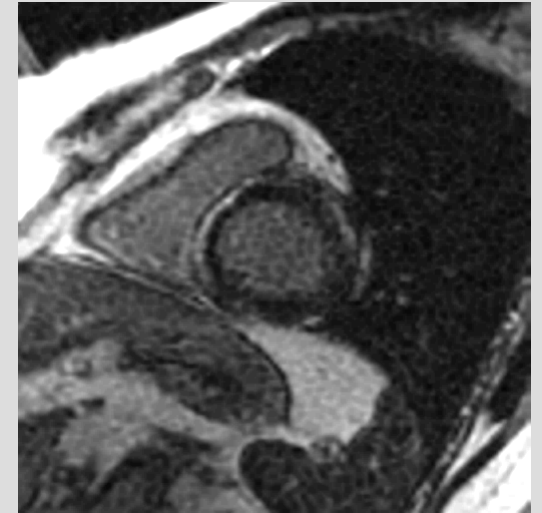
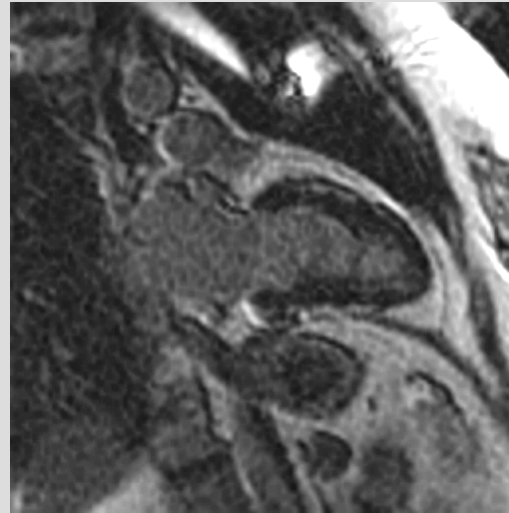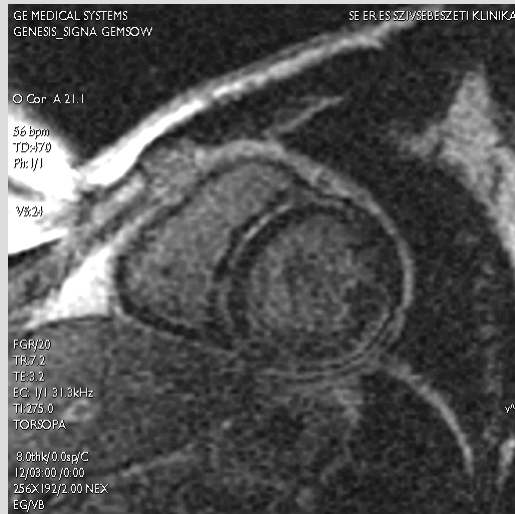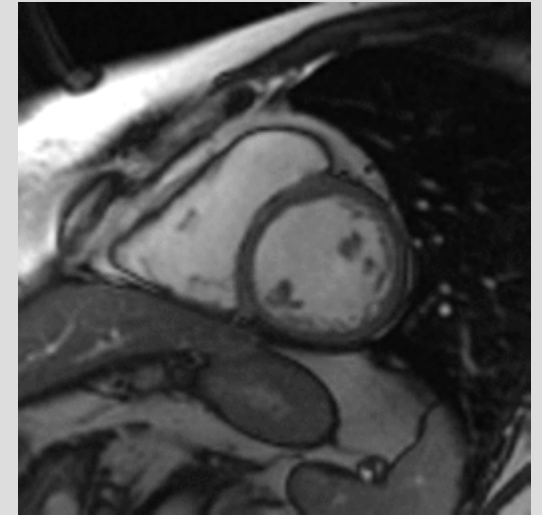
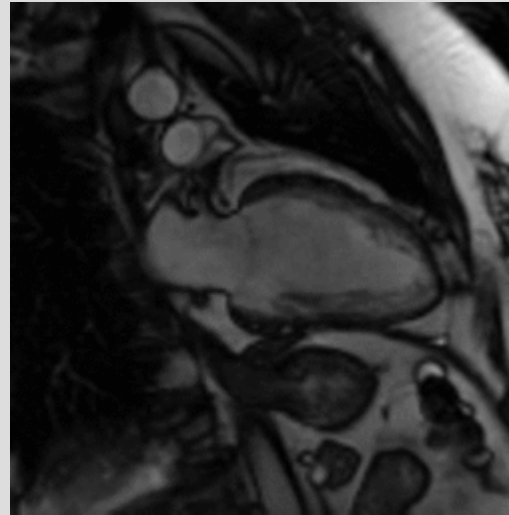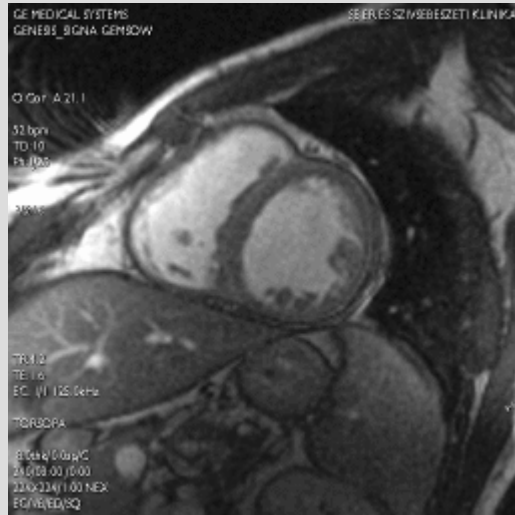# Non-compact CMP



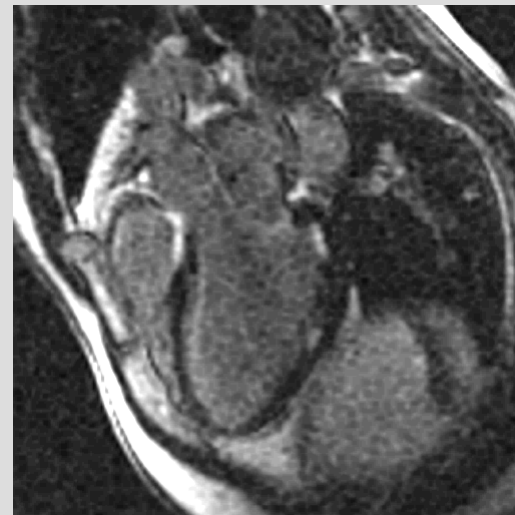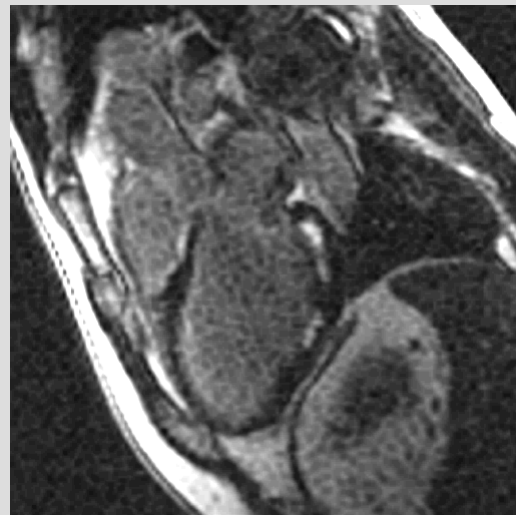
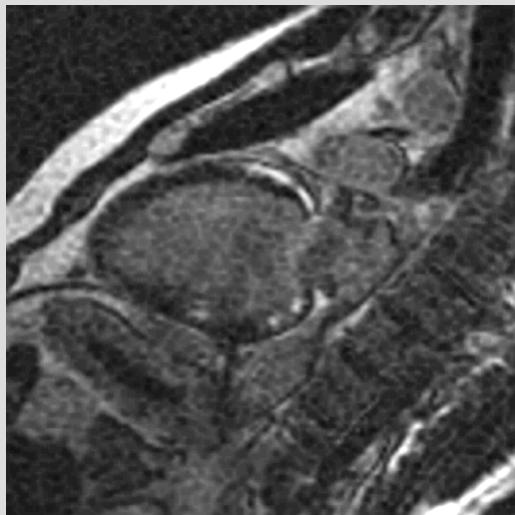
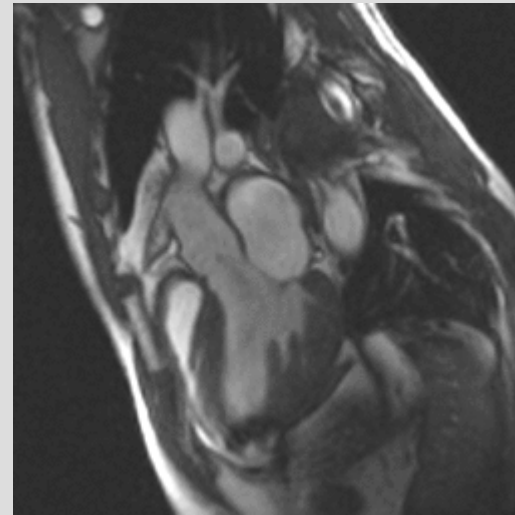
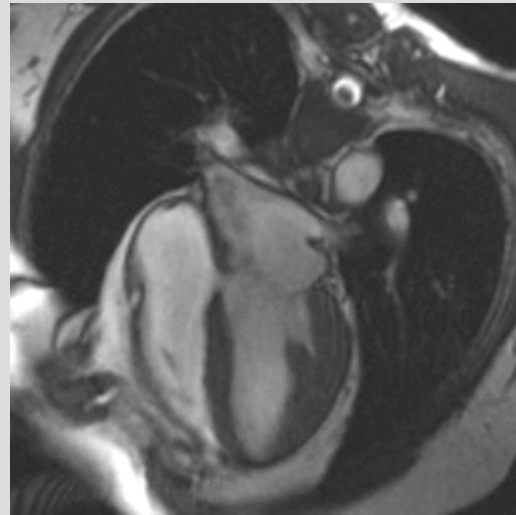
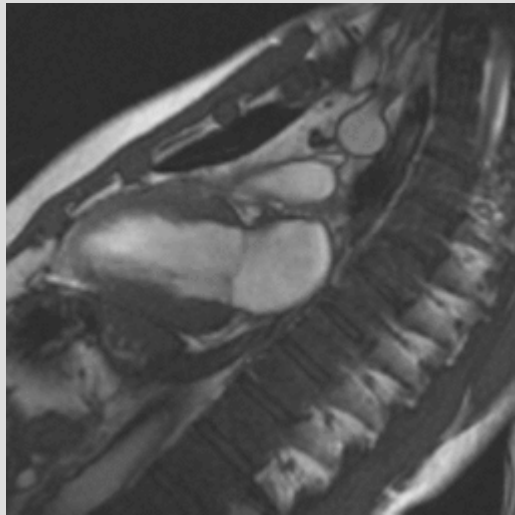
# ARVD



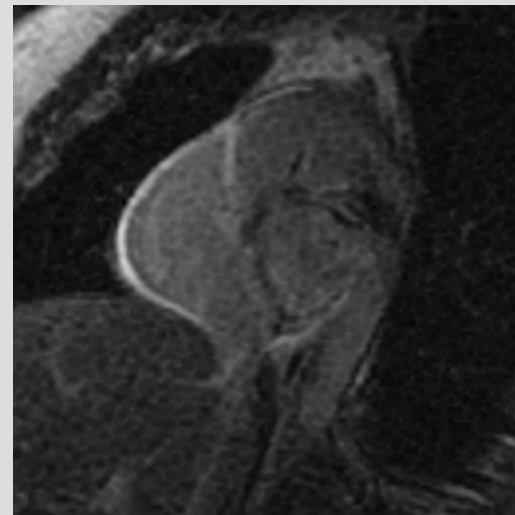
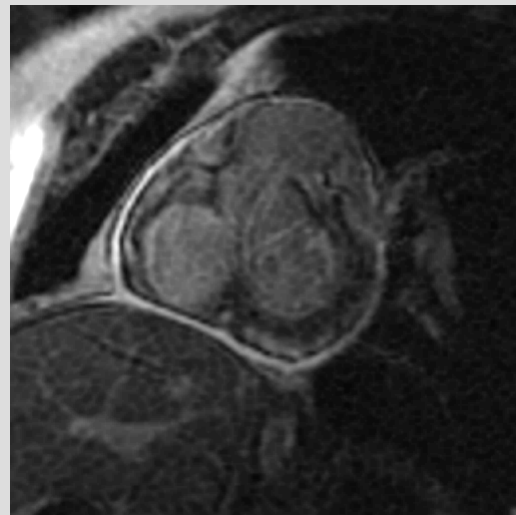
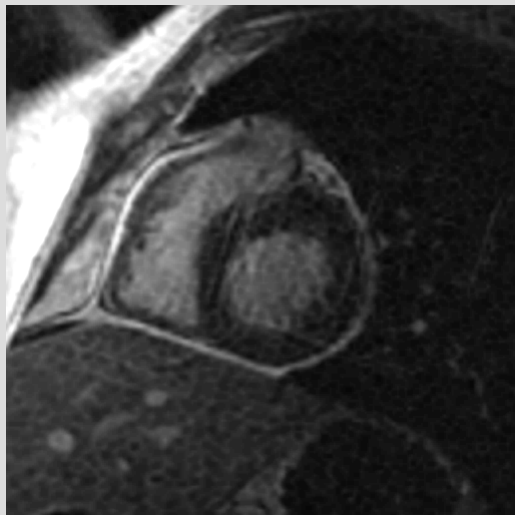
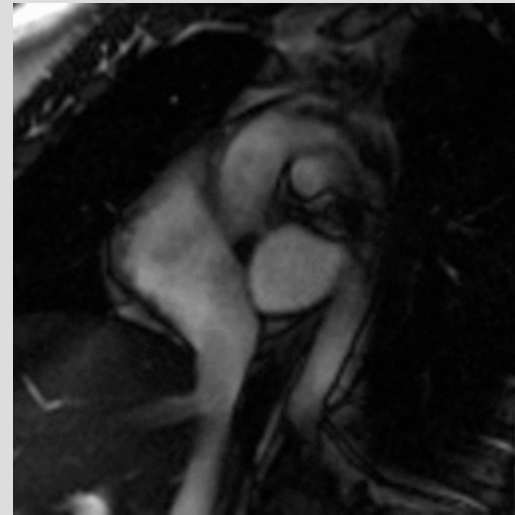
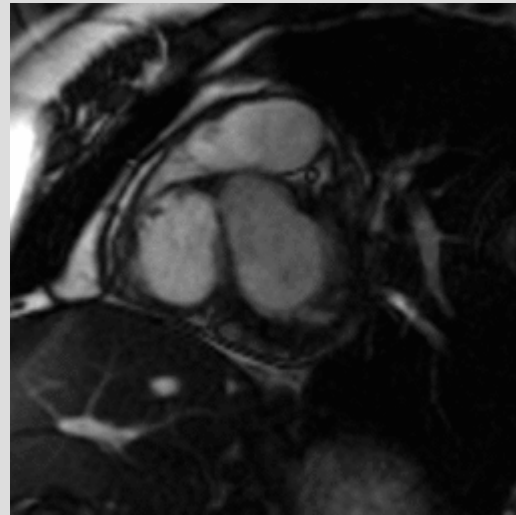
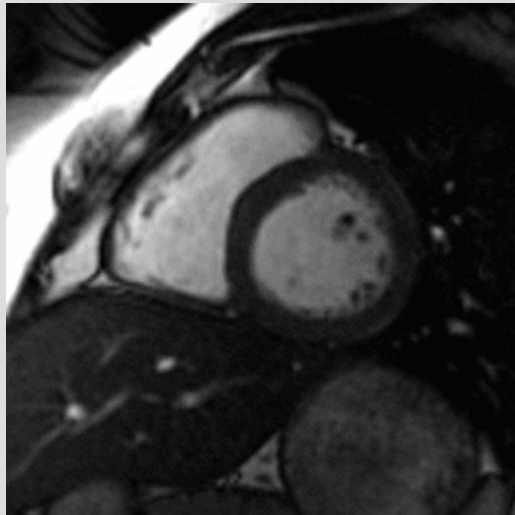
# Midmyocardial - myocarditis



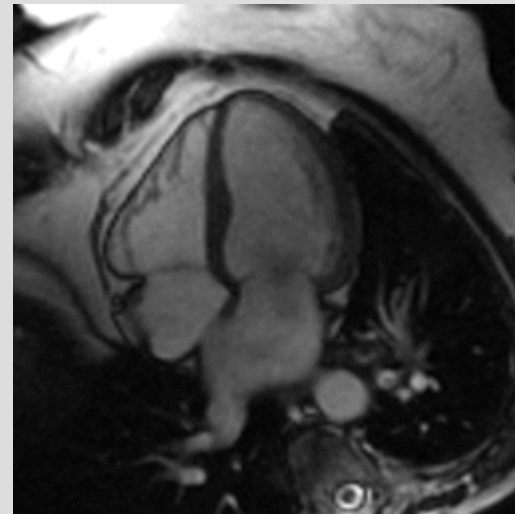
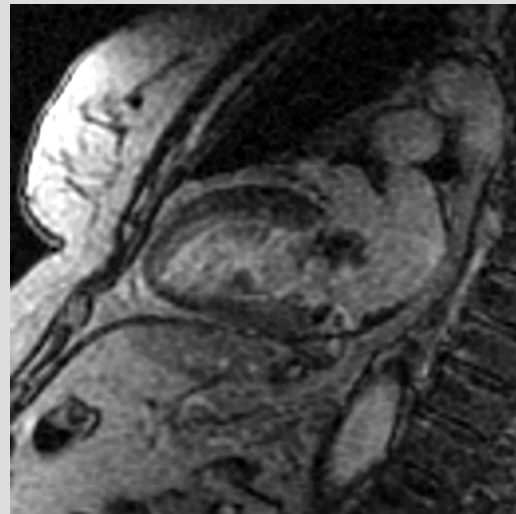
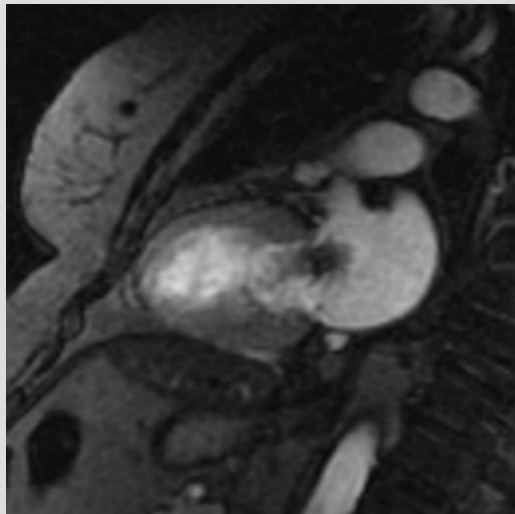
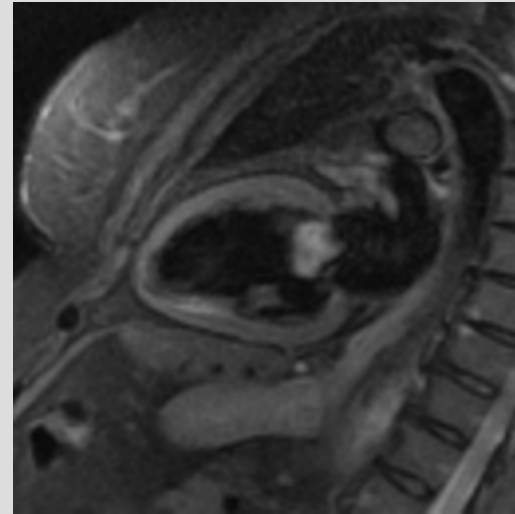
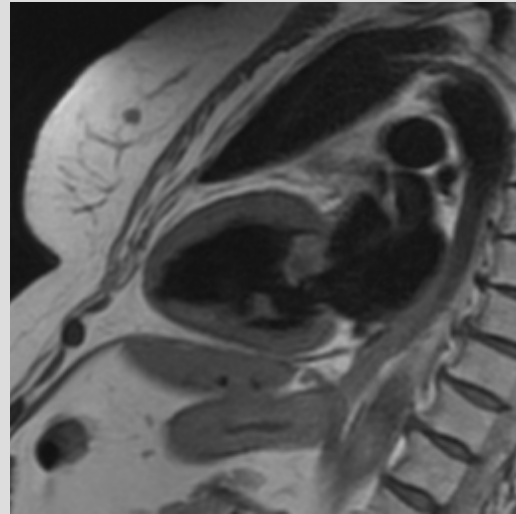
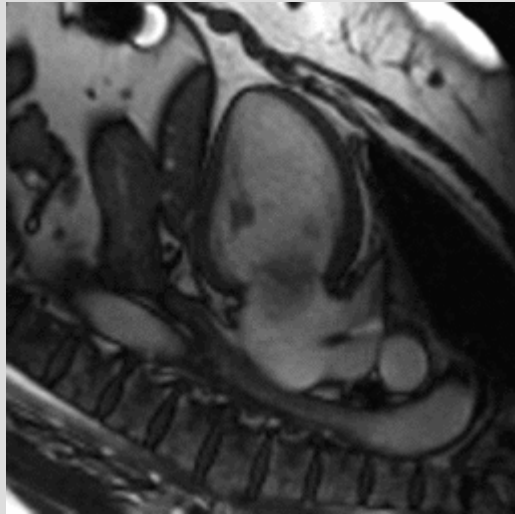
# Sarcoidosis



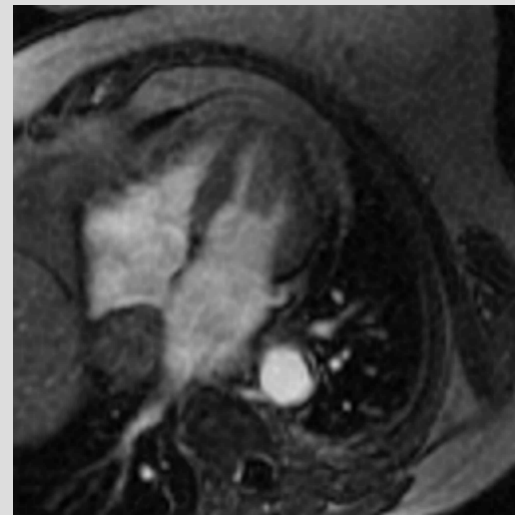
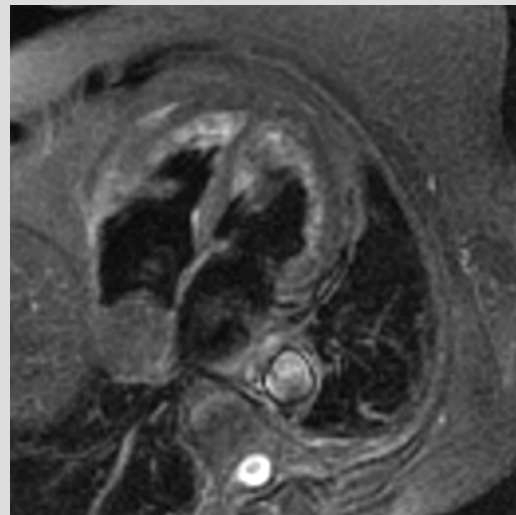
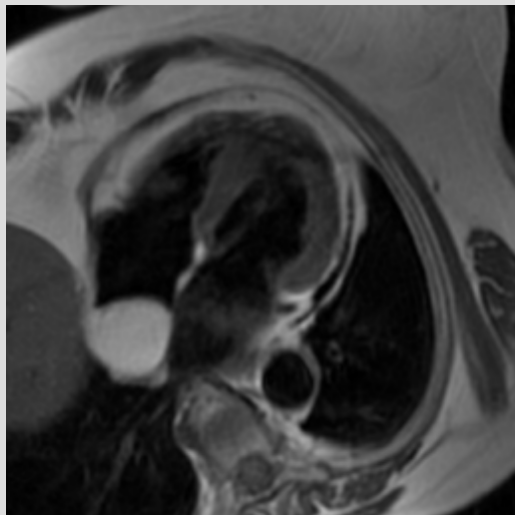
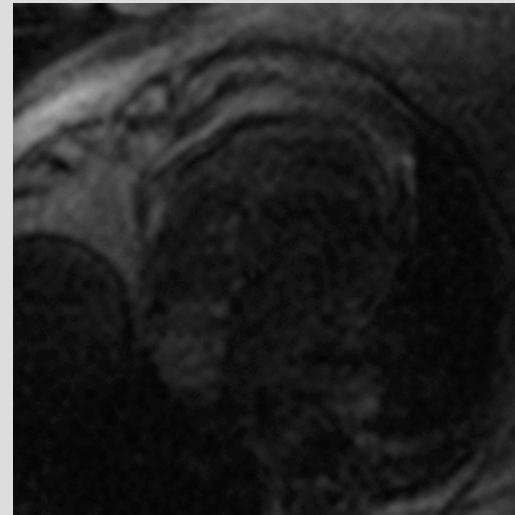
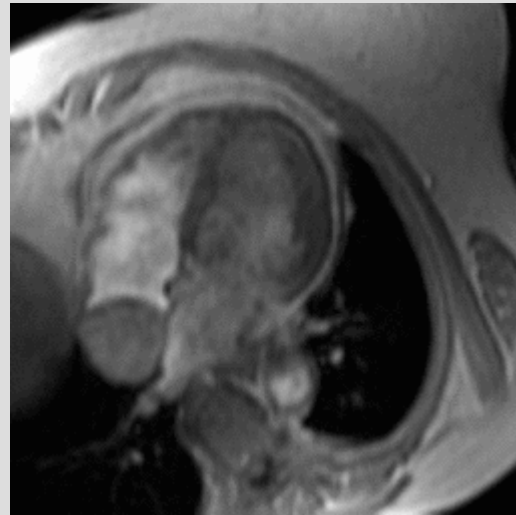
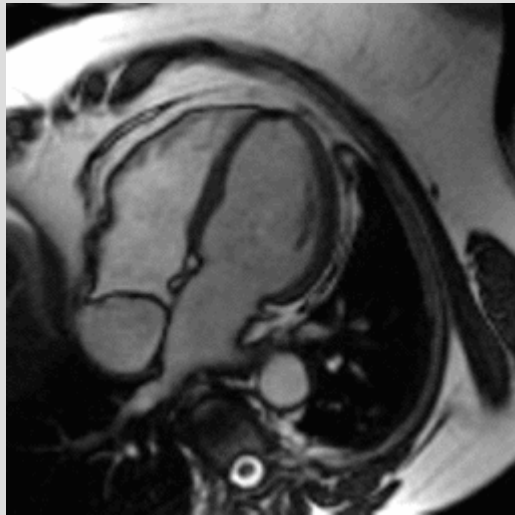# Pericarditis



# Left atrial myxoma

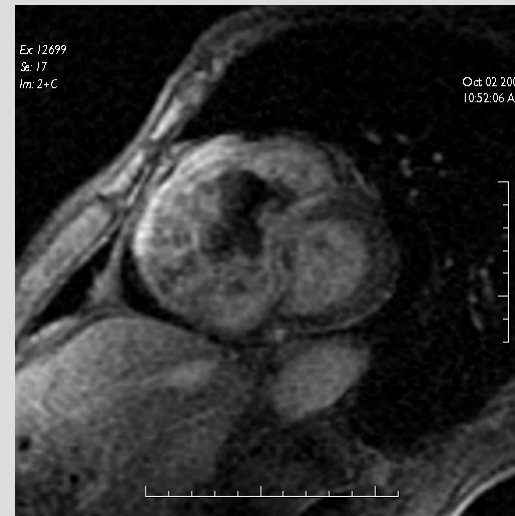
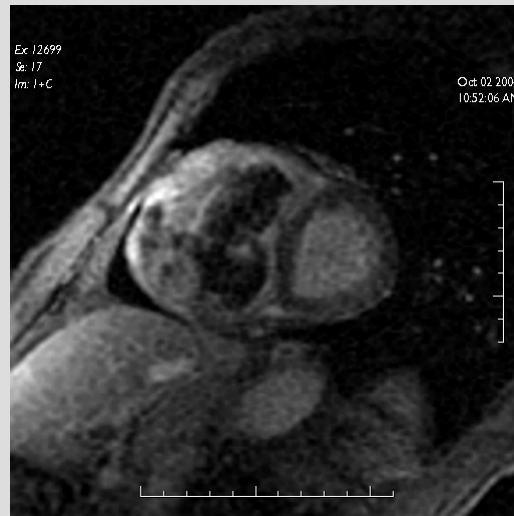
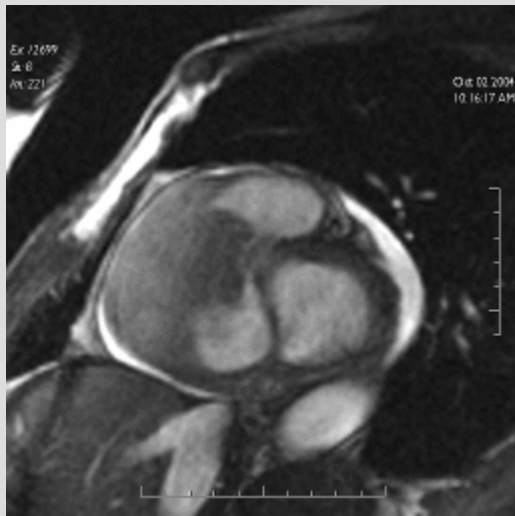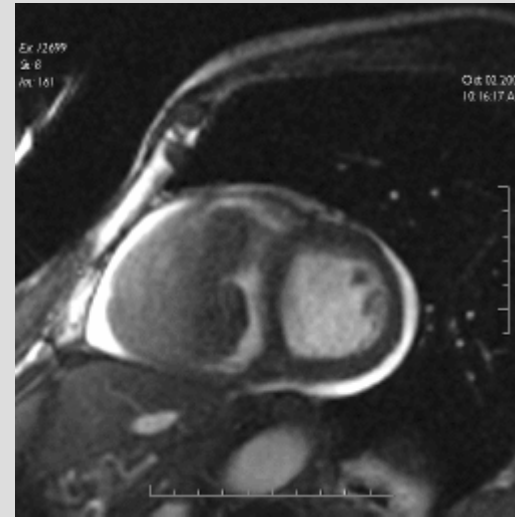
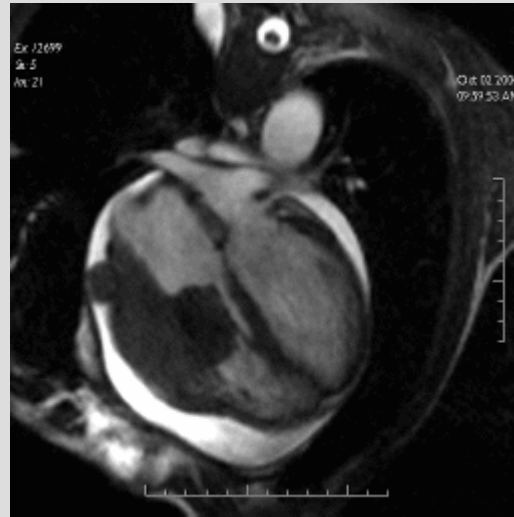

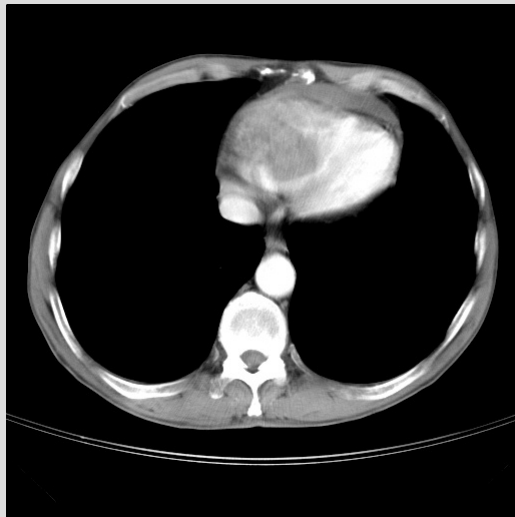
# Right atrial lipoma

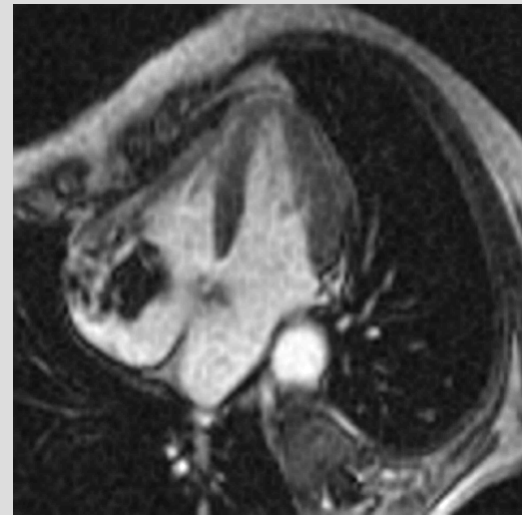
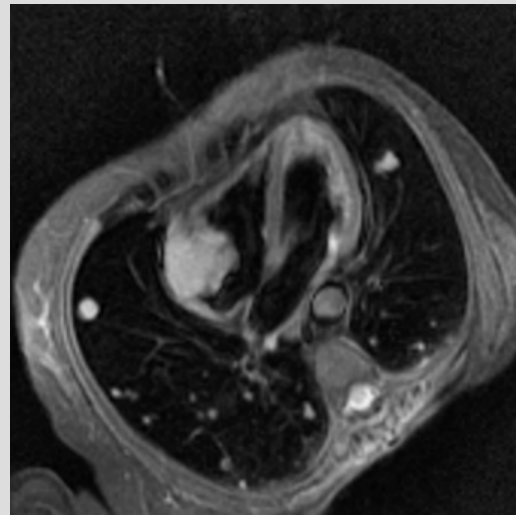
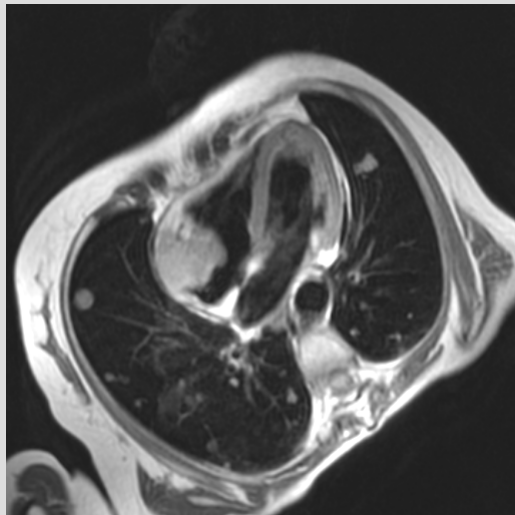
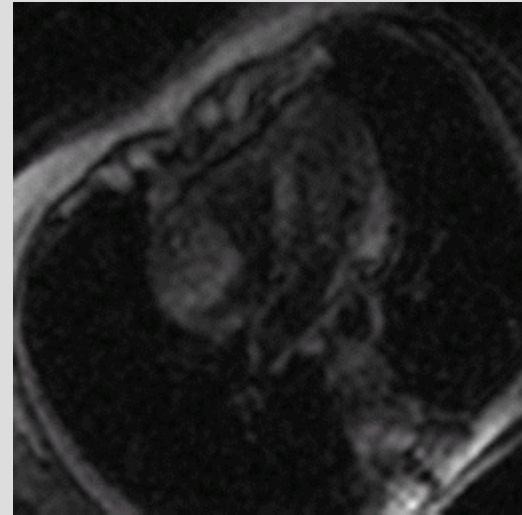
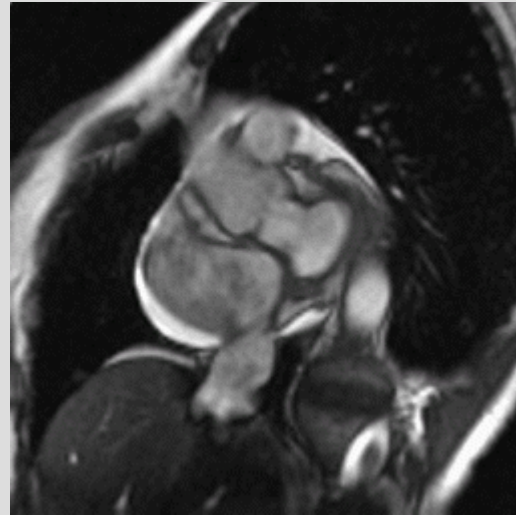
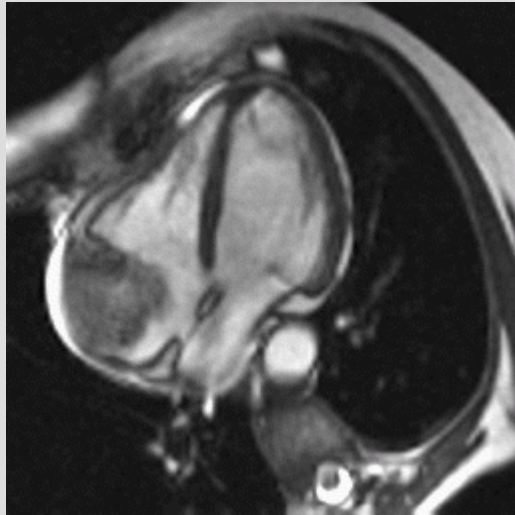




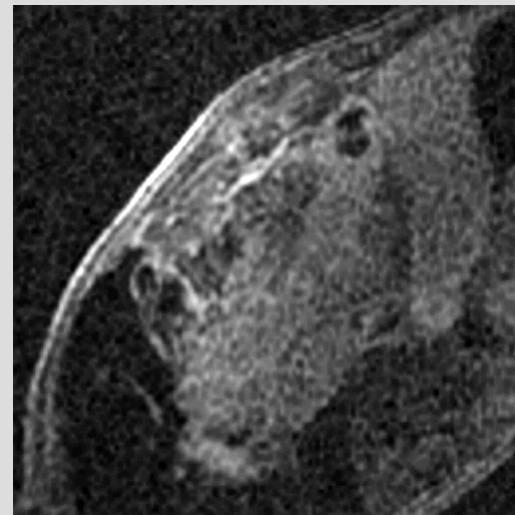
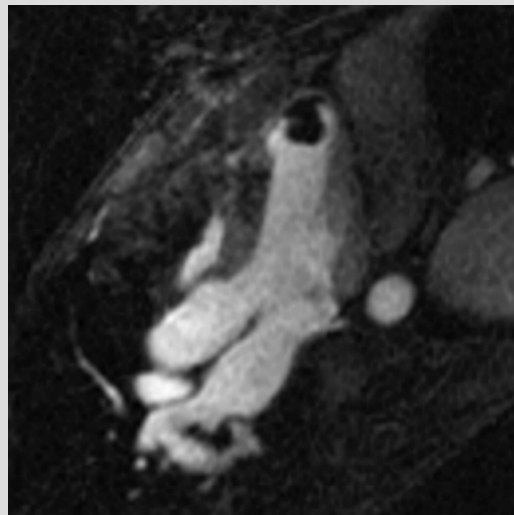
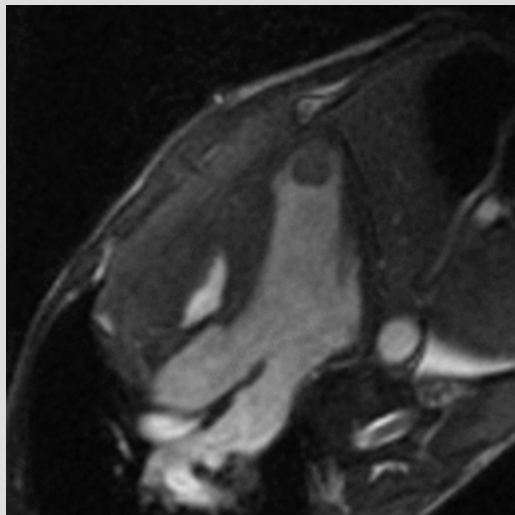
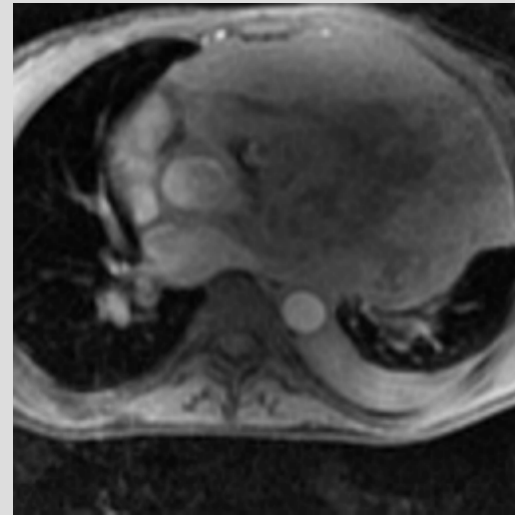
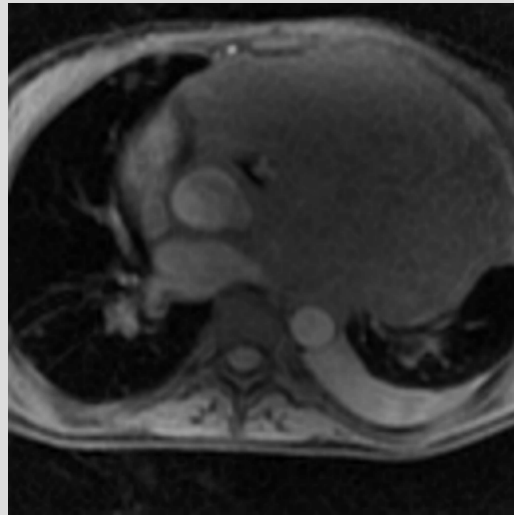
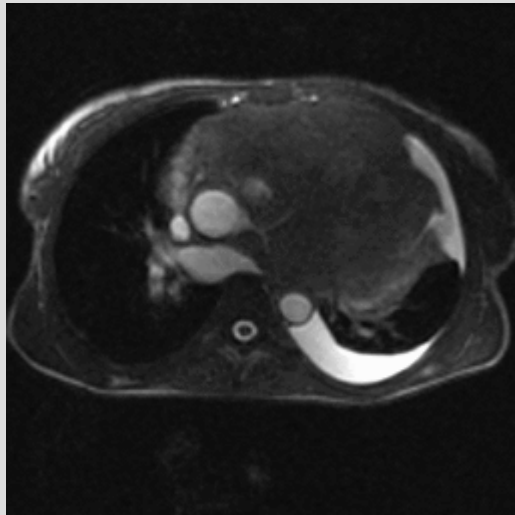
# Rectum tu meta



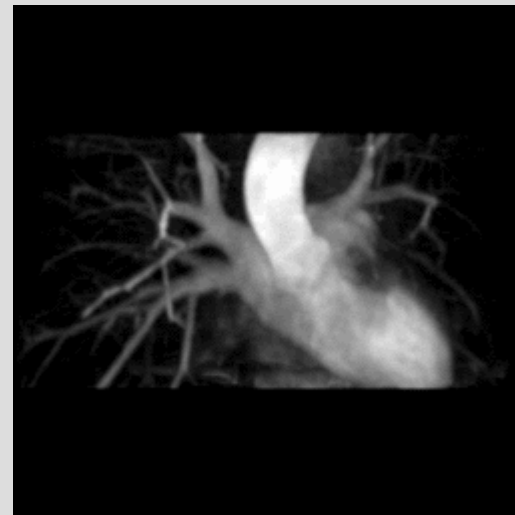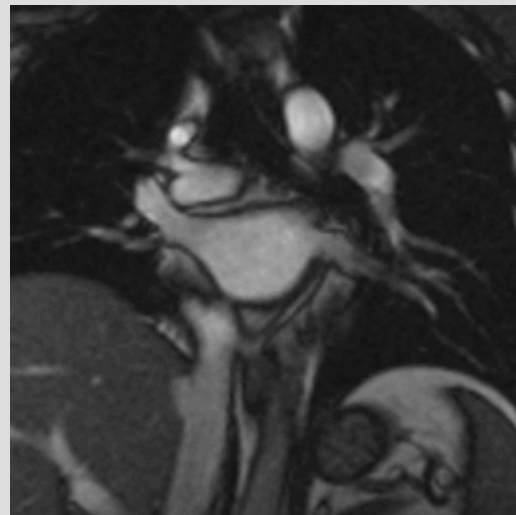
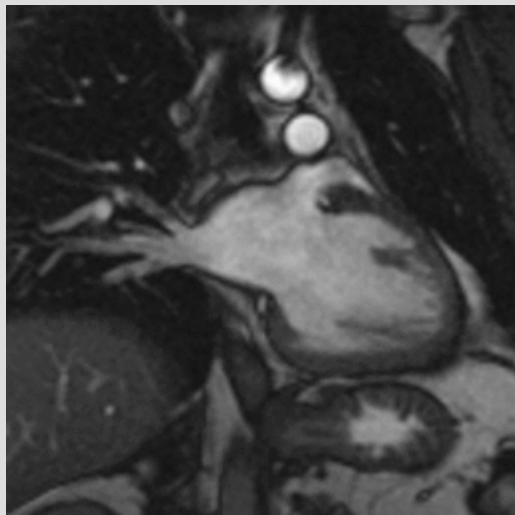
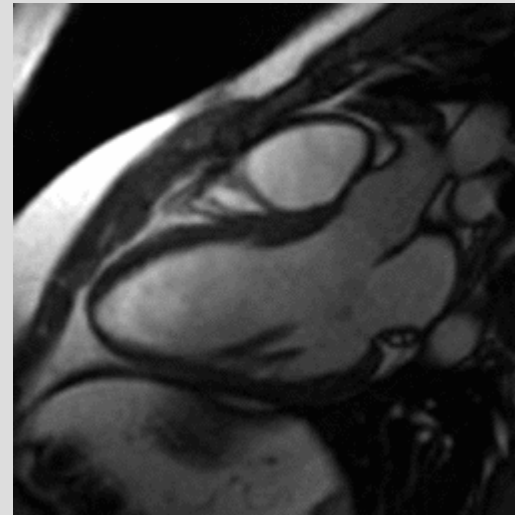
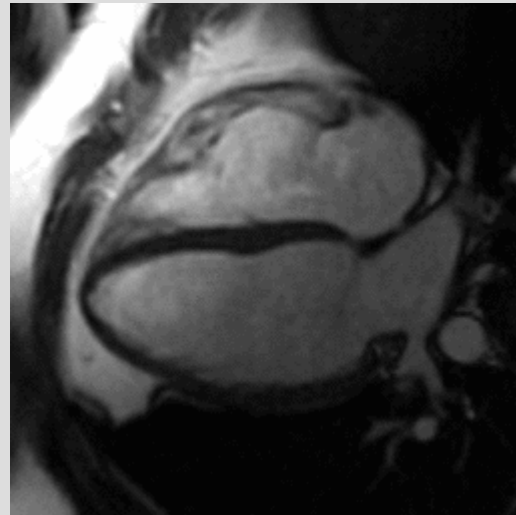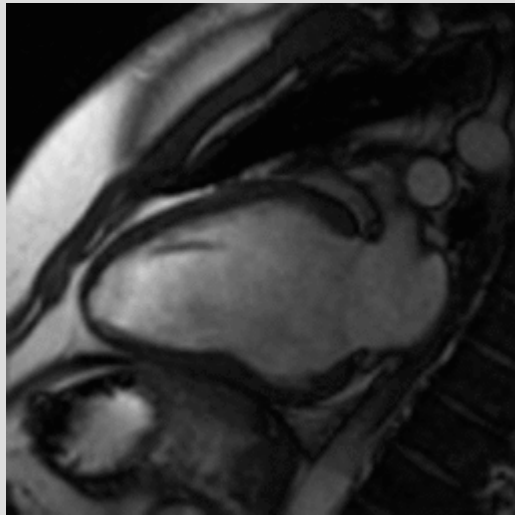
# Breast cc meta



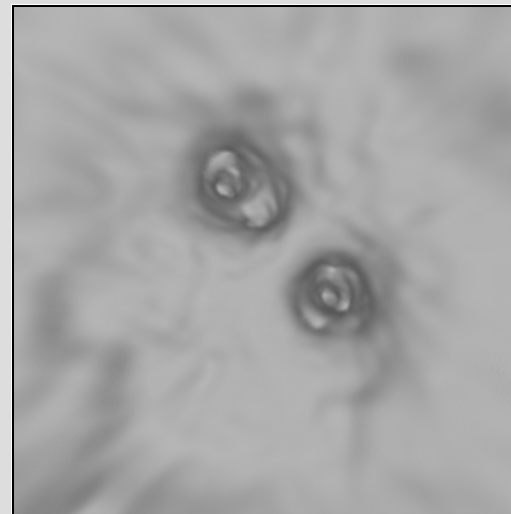
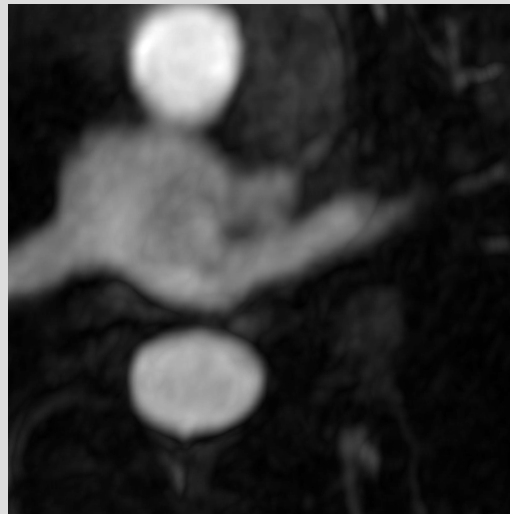
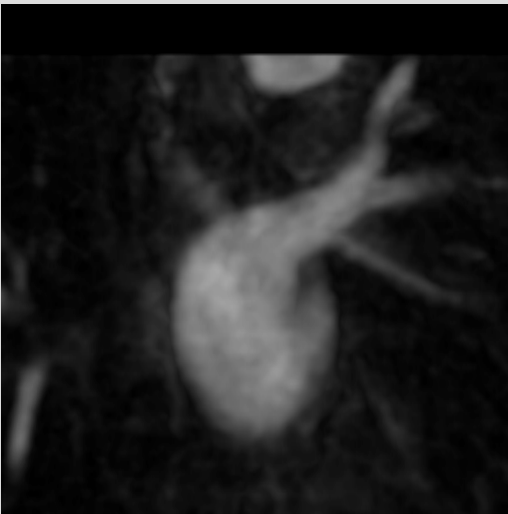

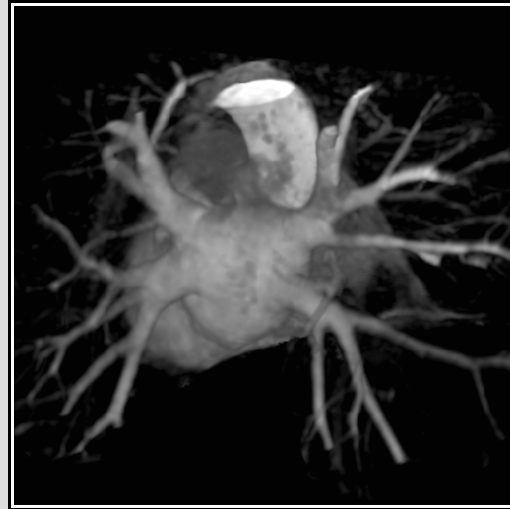
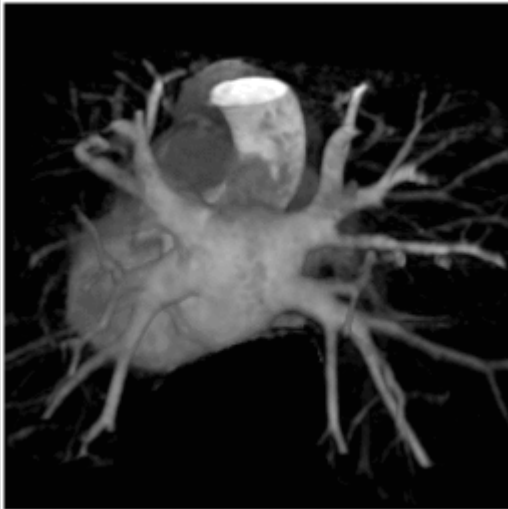
# Diffuse large cell NHL




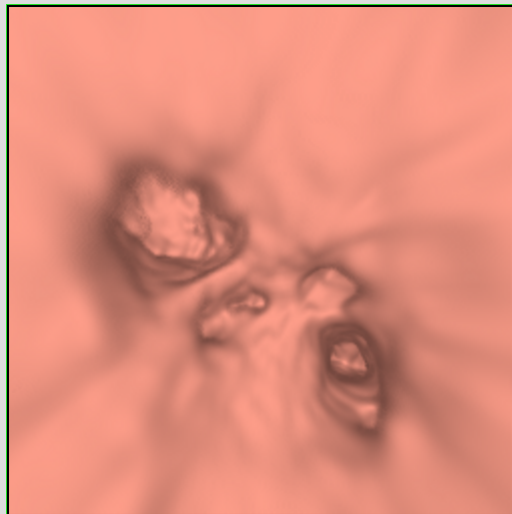

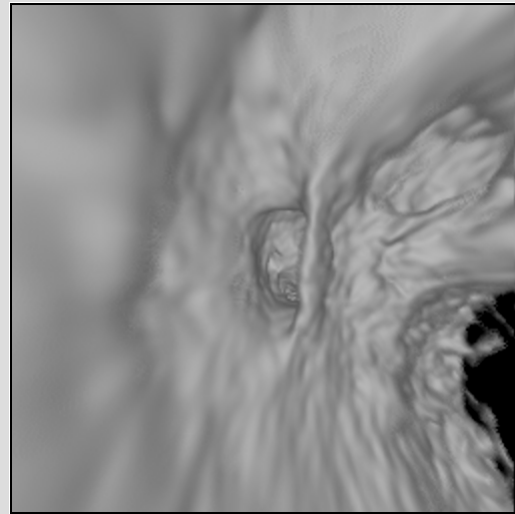
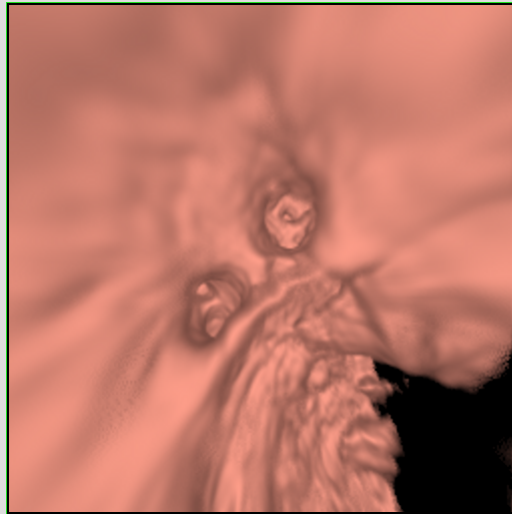

# Vena pulmonalis




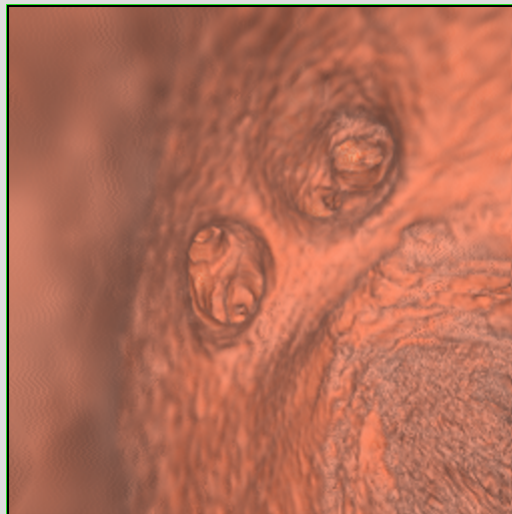
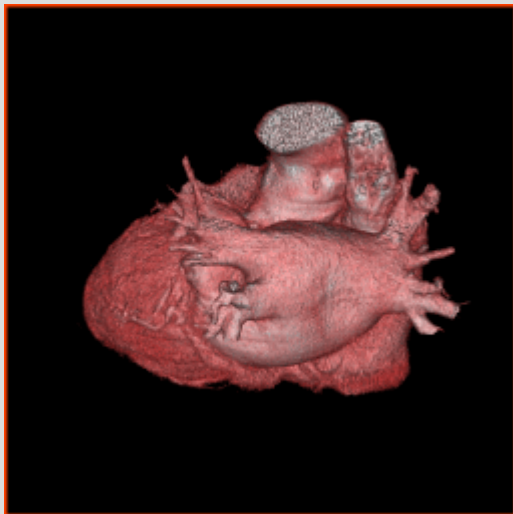


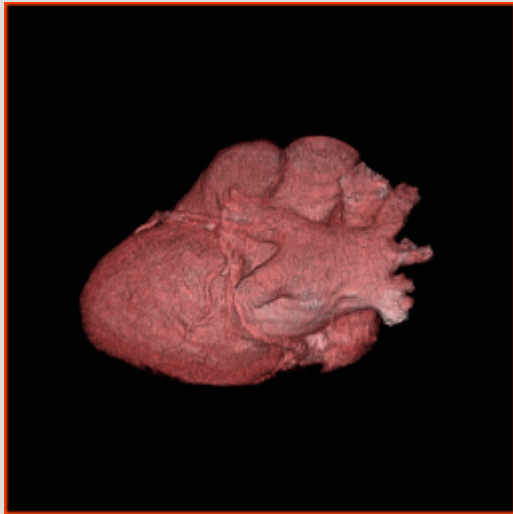
# Vena pulmonalis



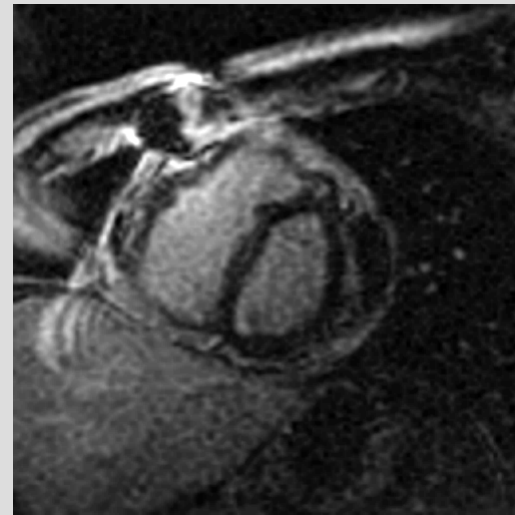
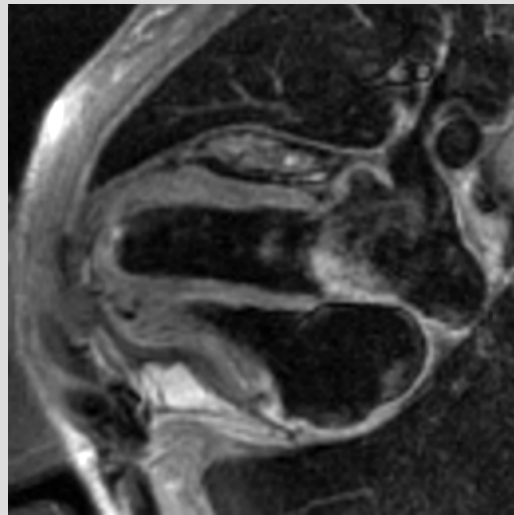
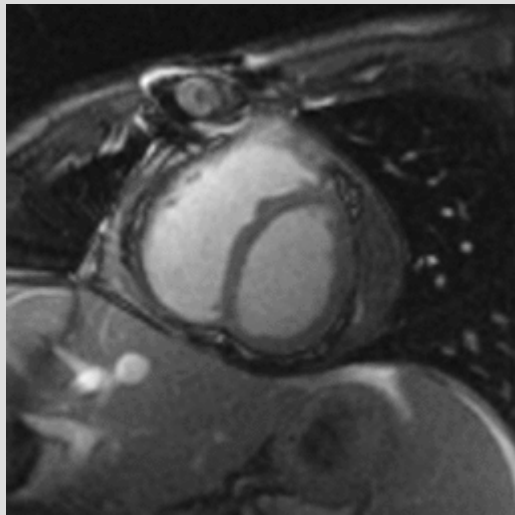
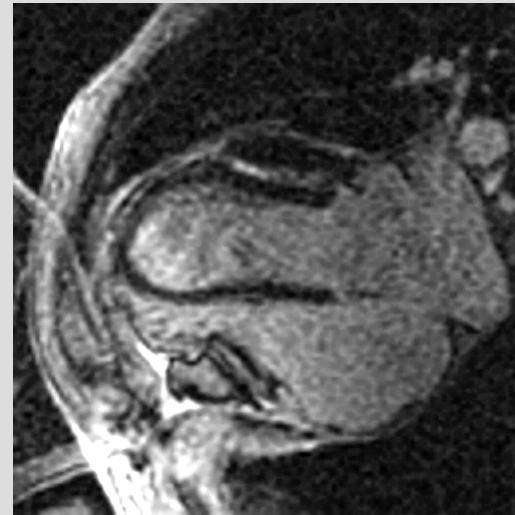
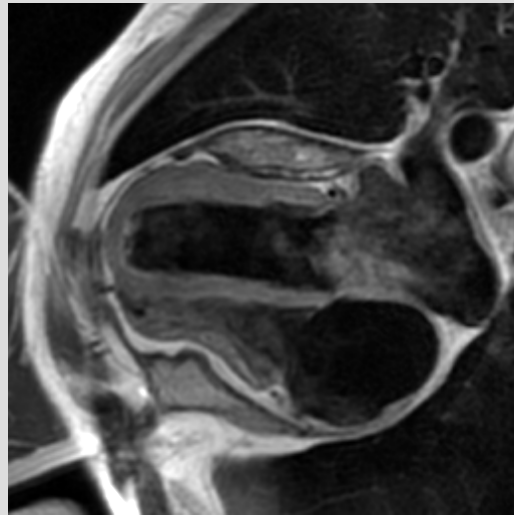
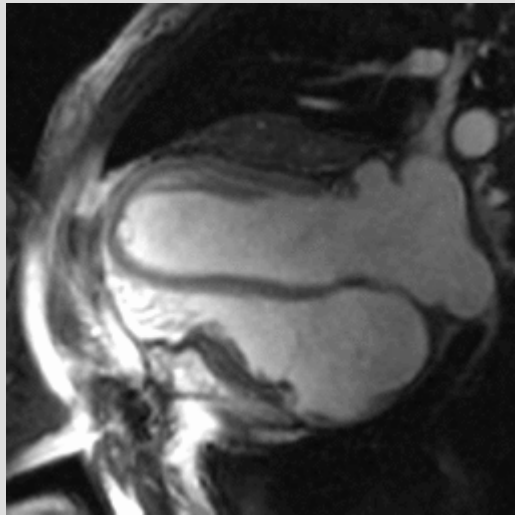
# Endo



# CT

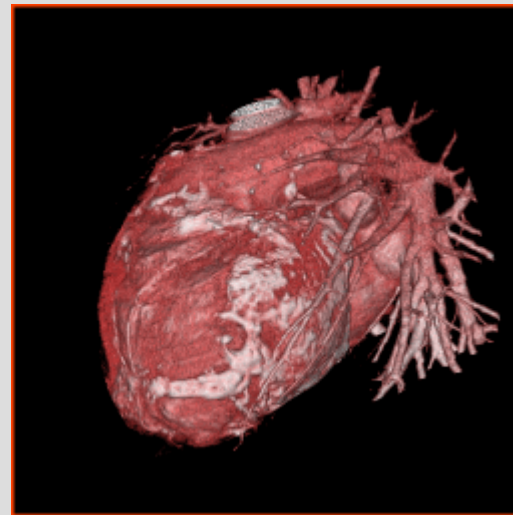
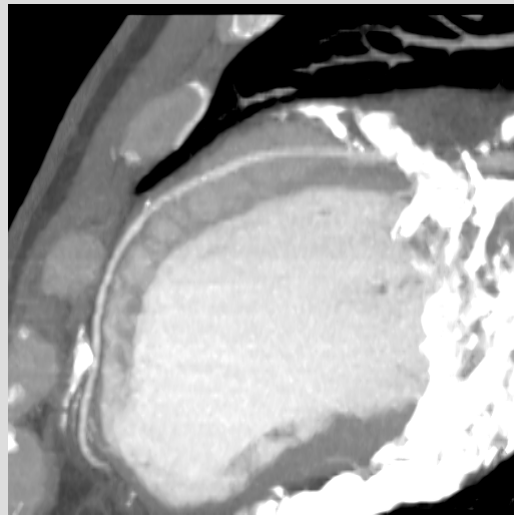
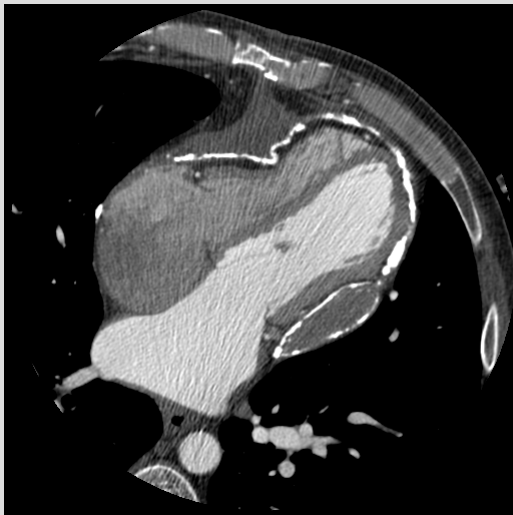
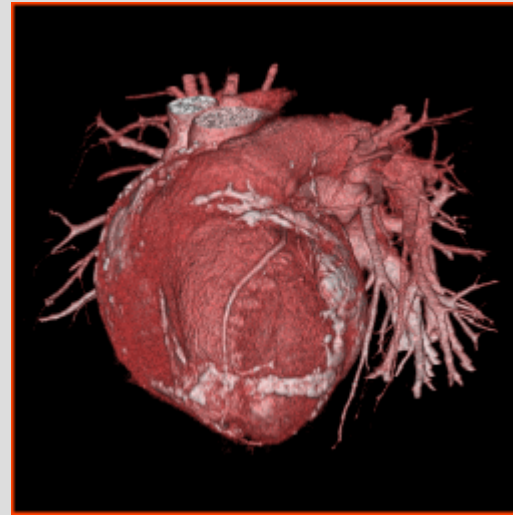
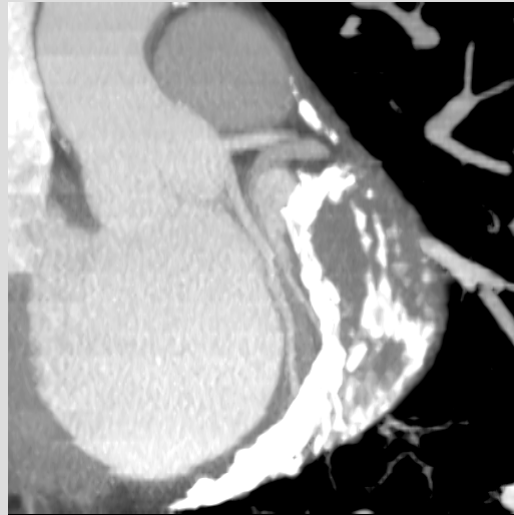
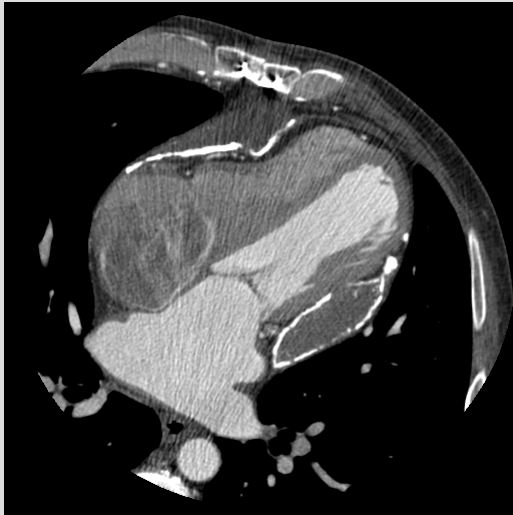

# Constrictive MR


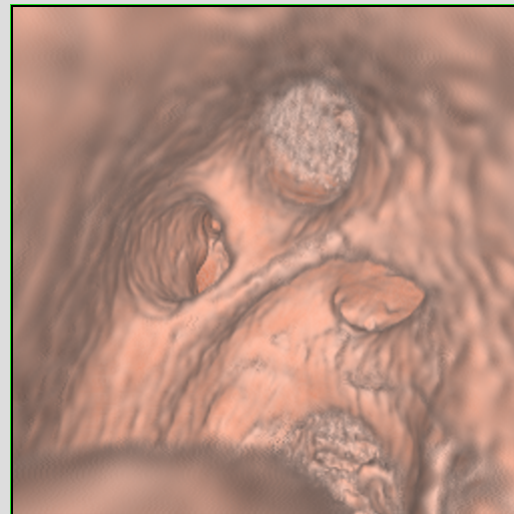
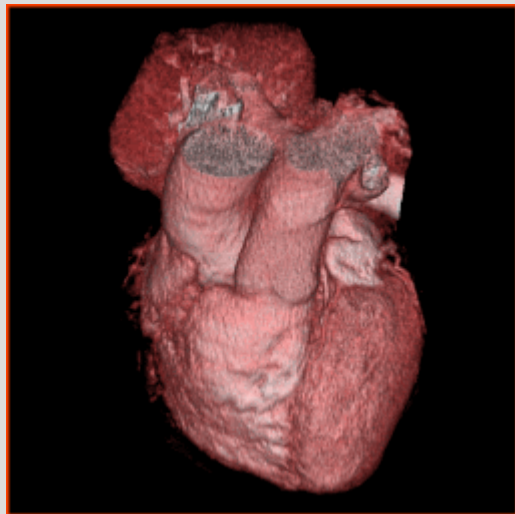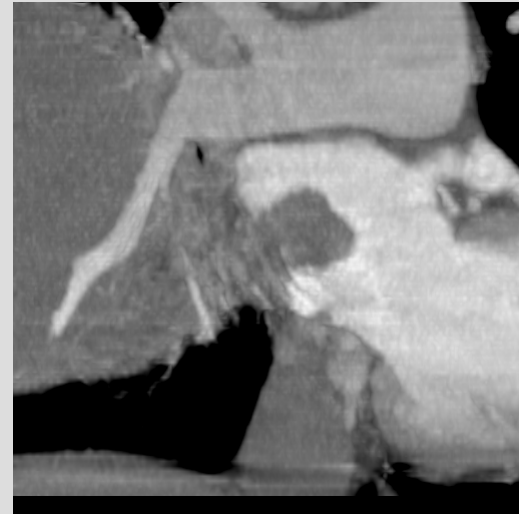
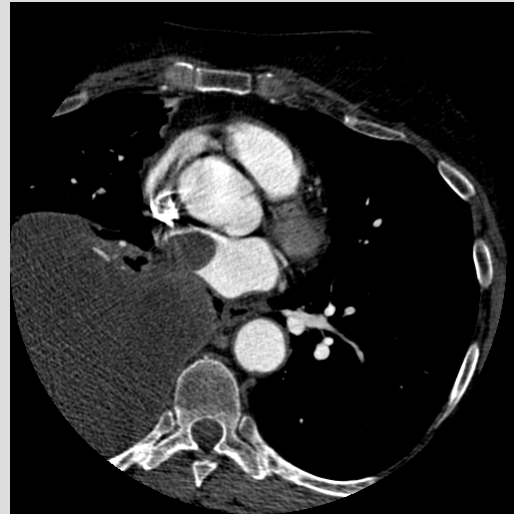
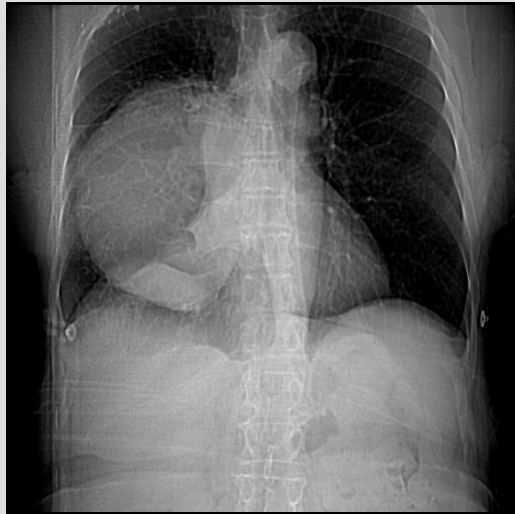




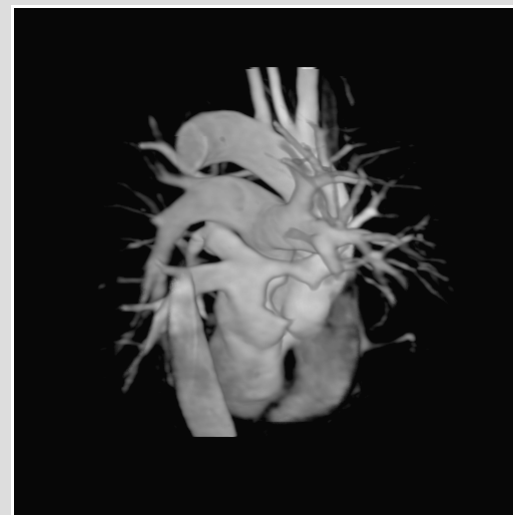
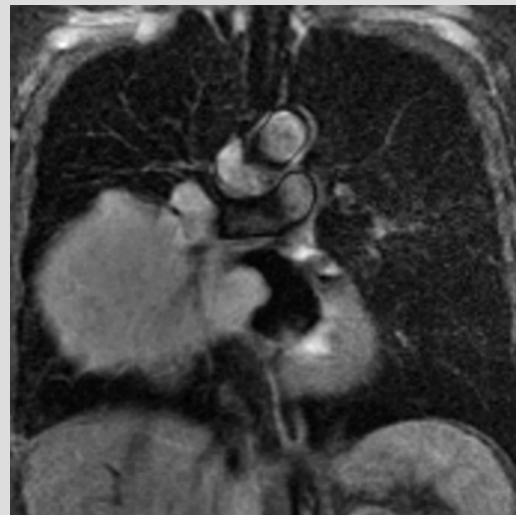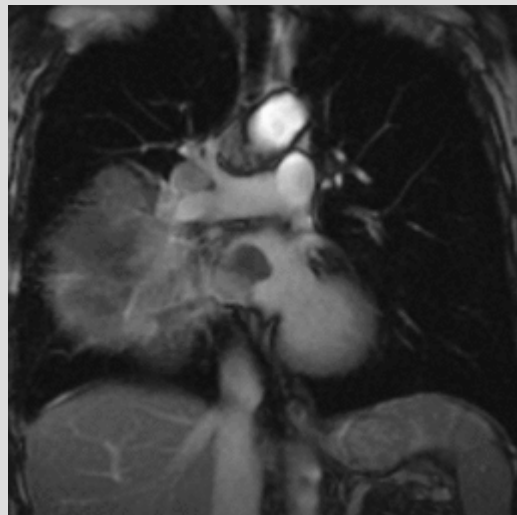
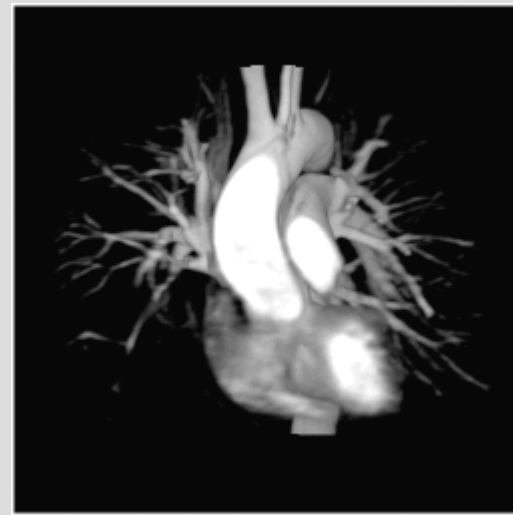
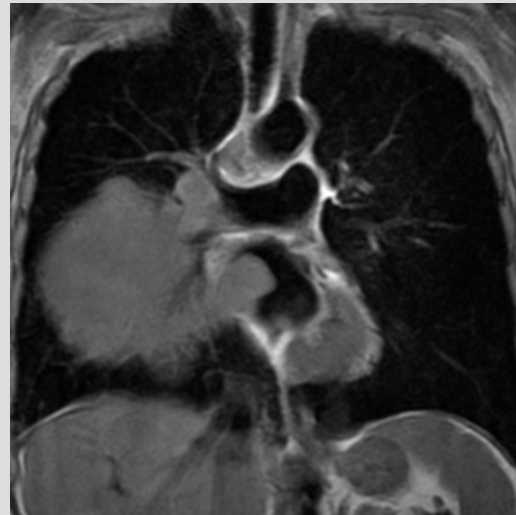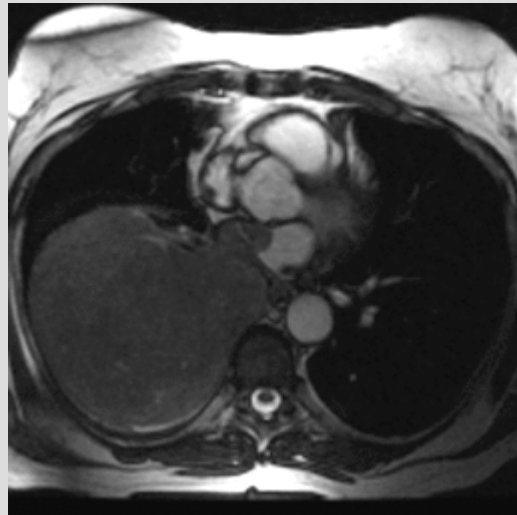
# Constrictive CT



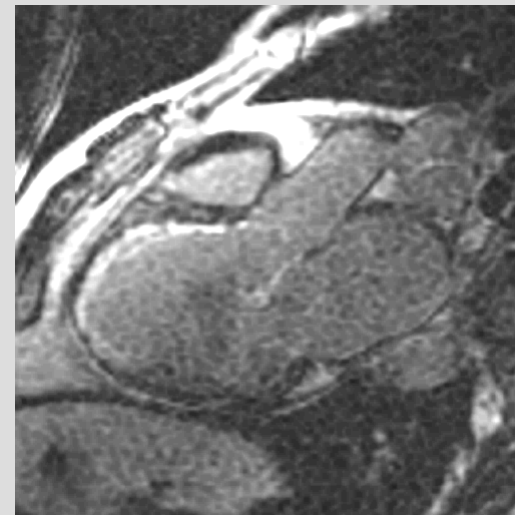
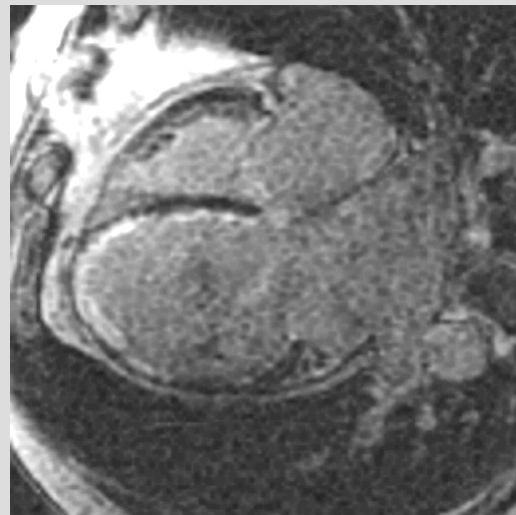
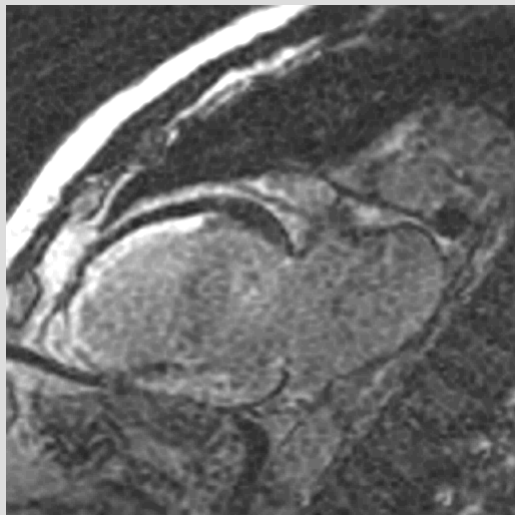
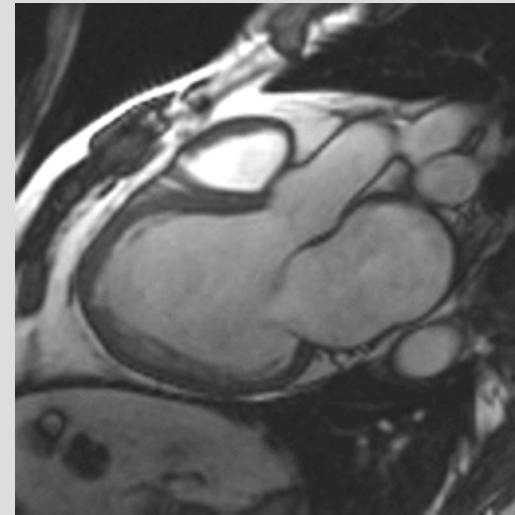
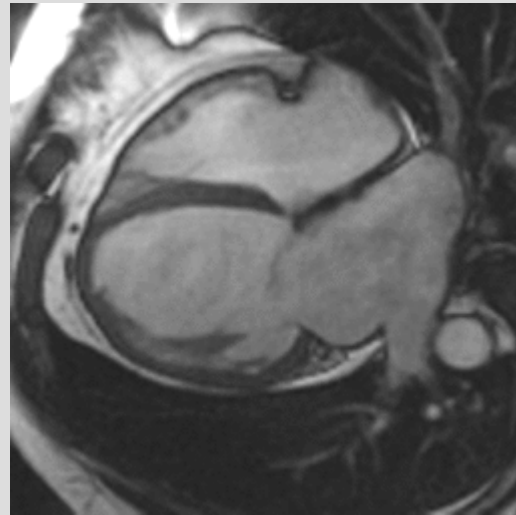
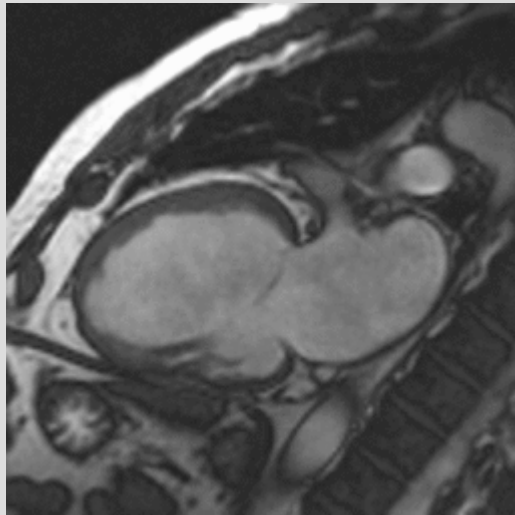
# Lung cc CT



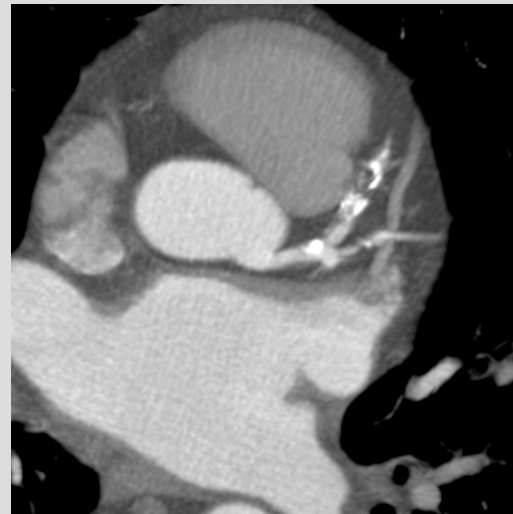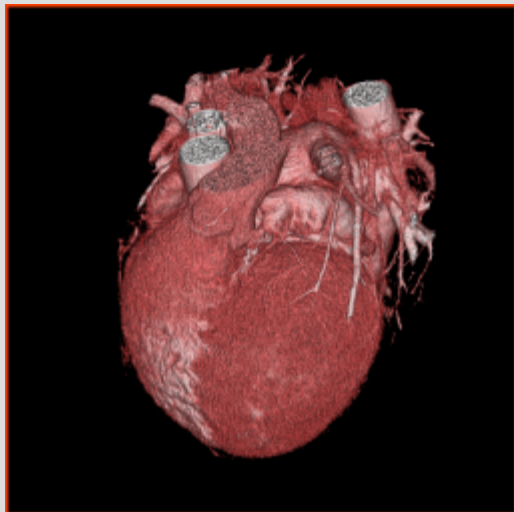
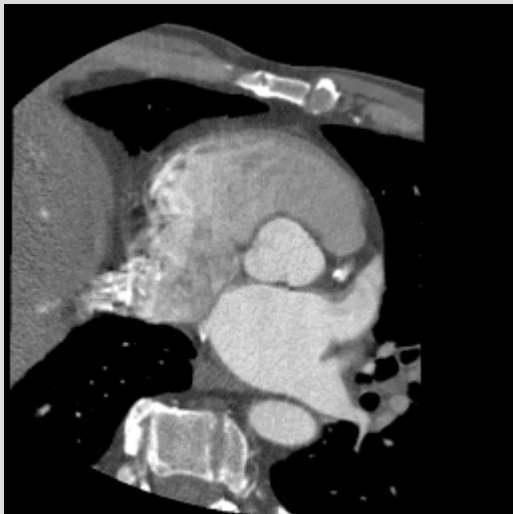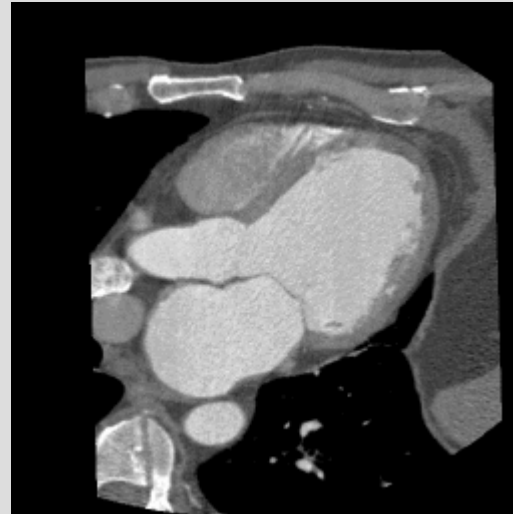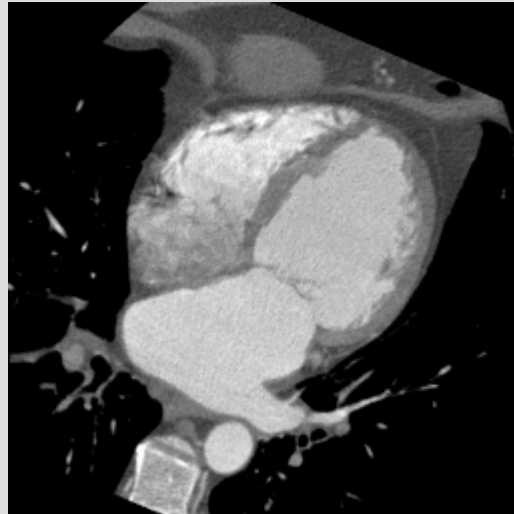
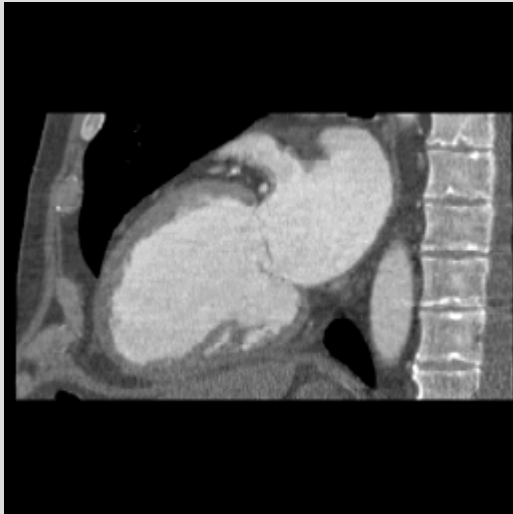# Lung cc MR



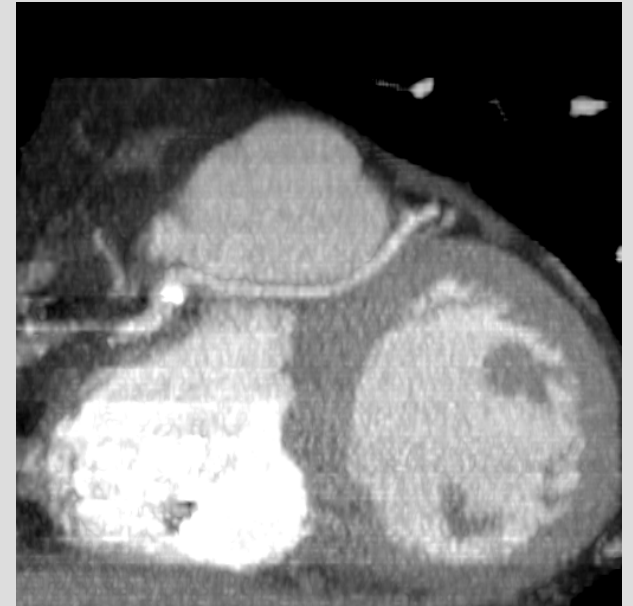
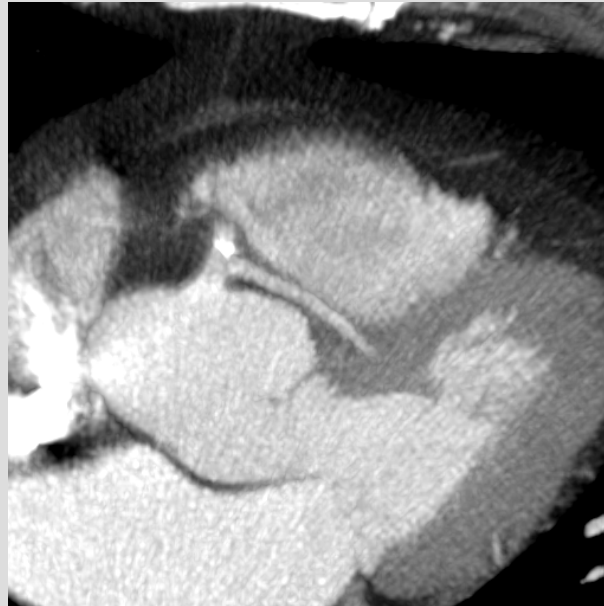
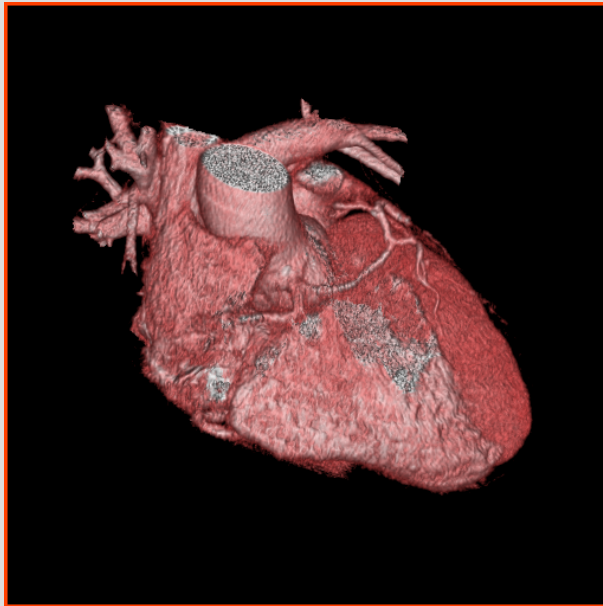# MR prior to LV reduction surgery



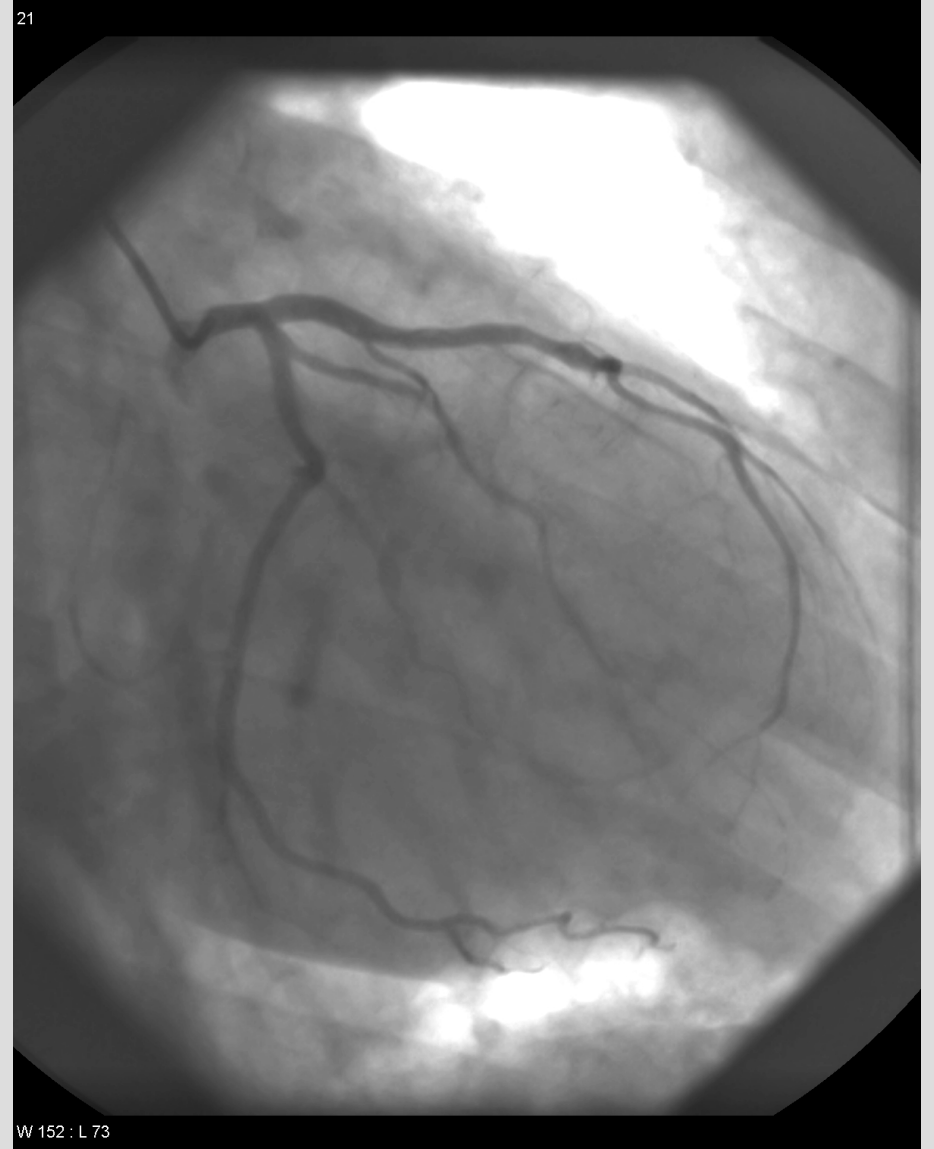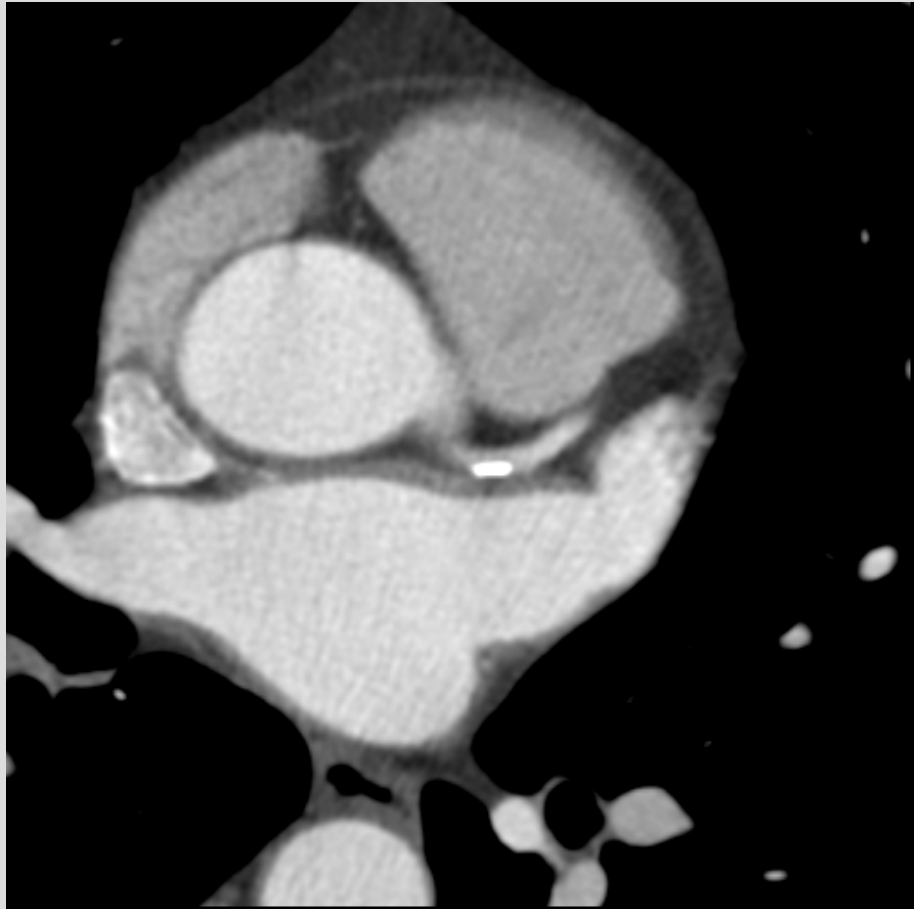
# CT prior to LV reduction surgery



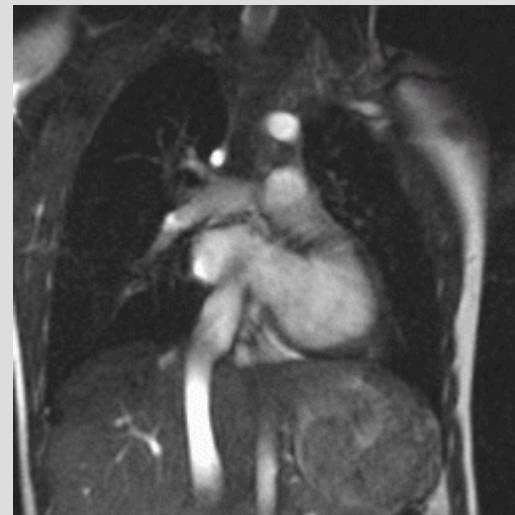
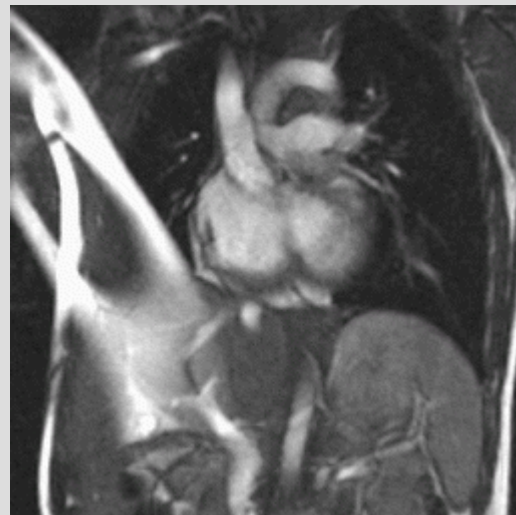
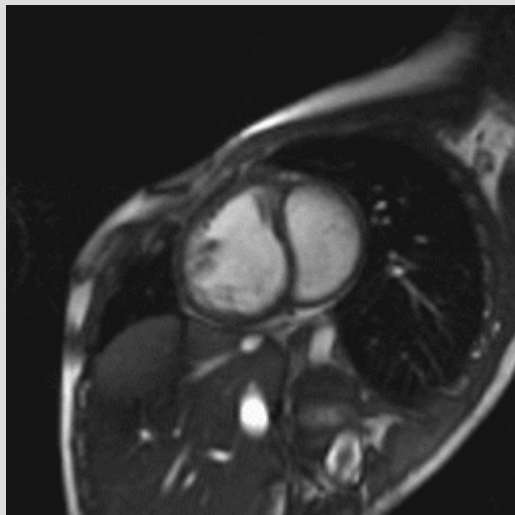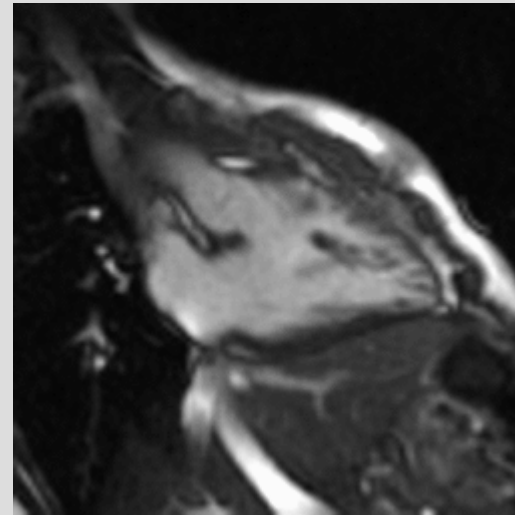
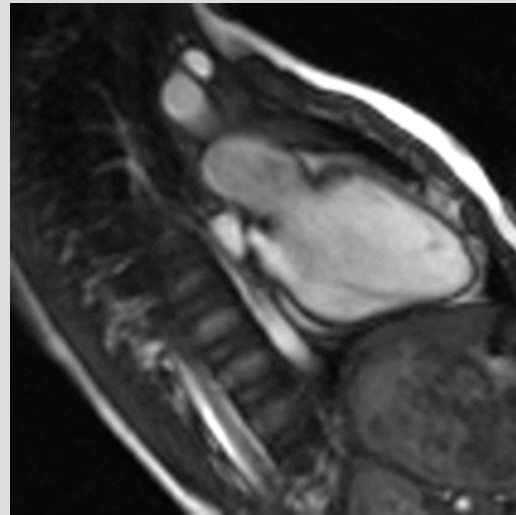
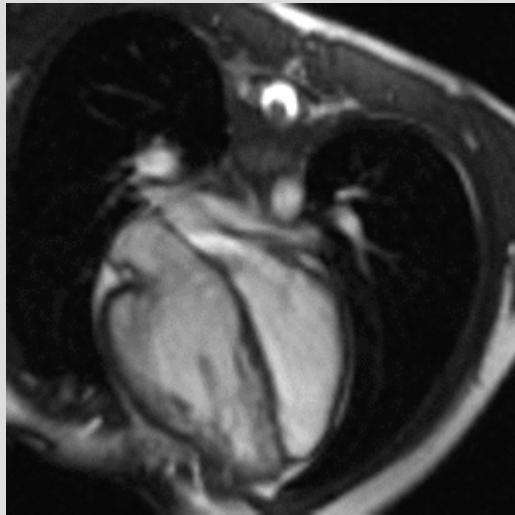# Anomalous coronary origin



# Stenosis CTA vs CXA

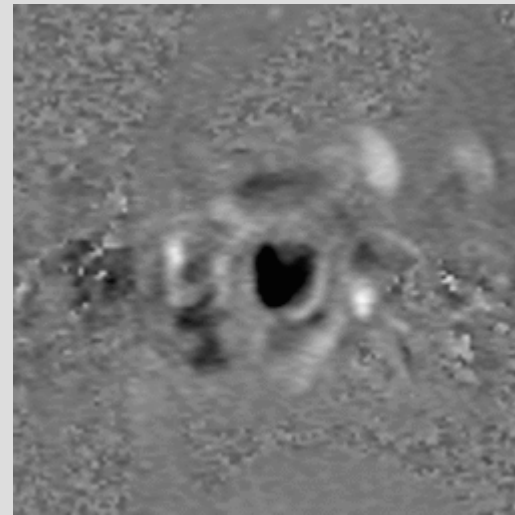
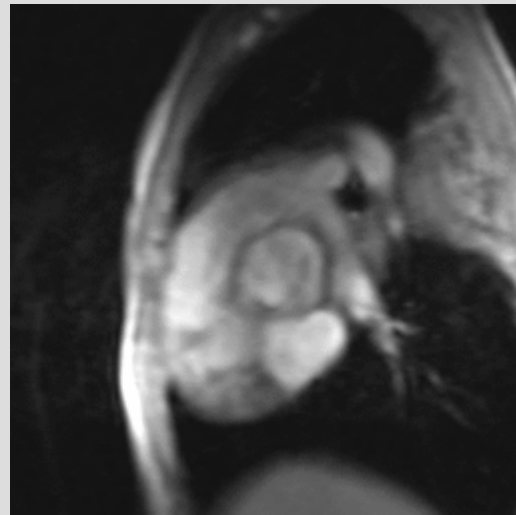
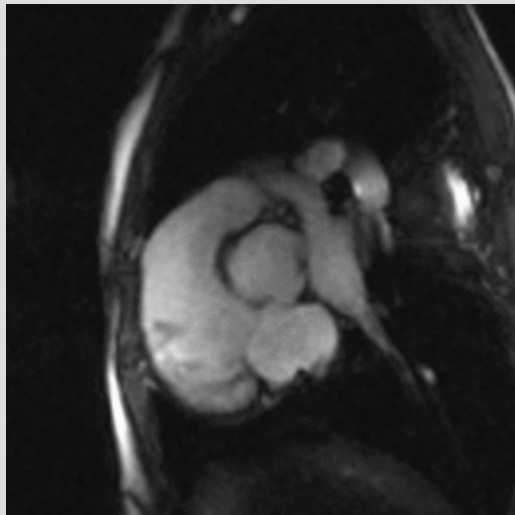
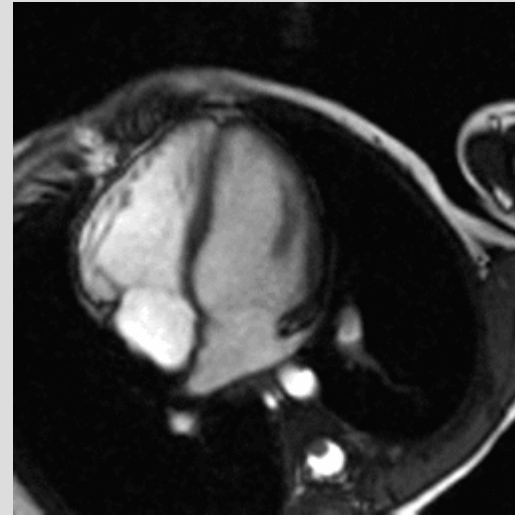
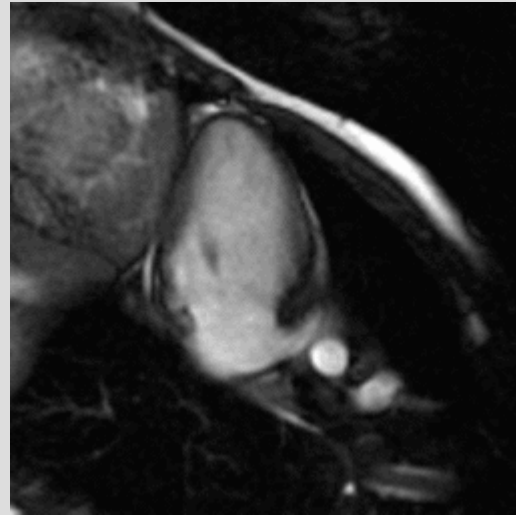
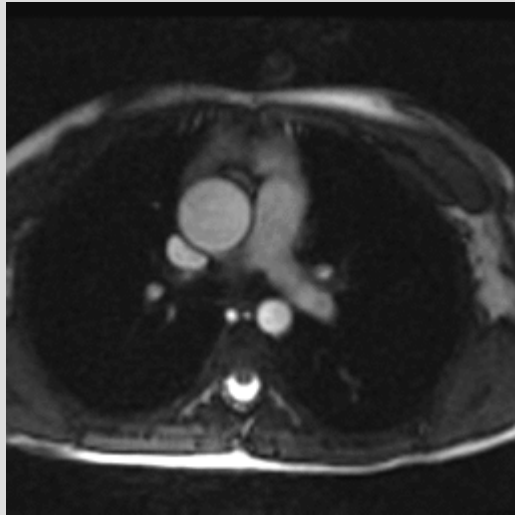


# TGA: post.op. Senning

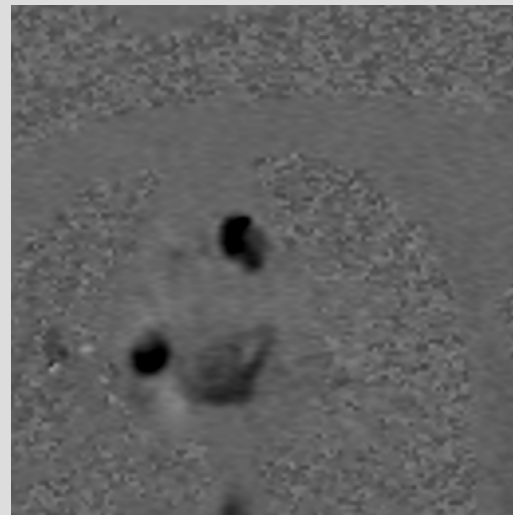
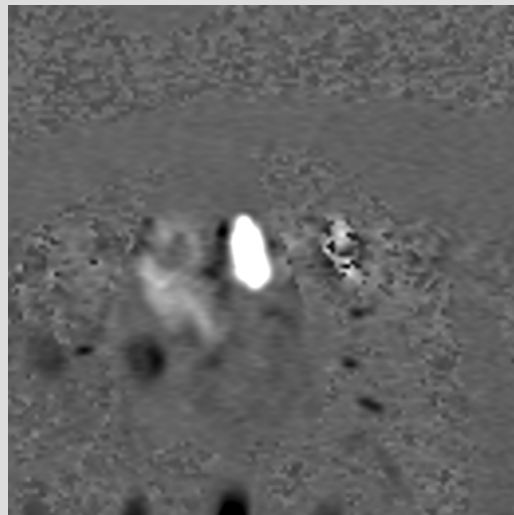
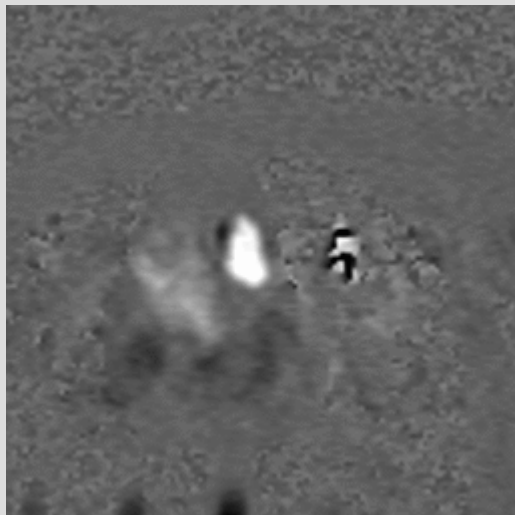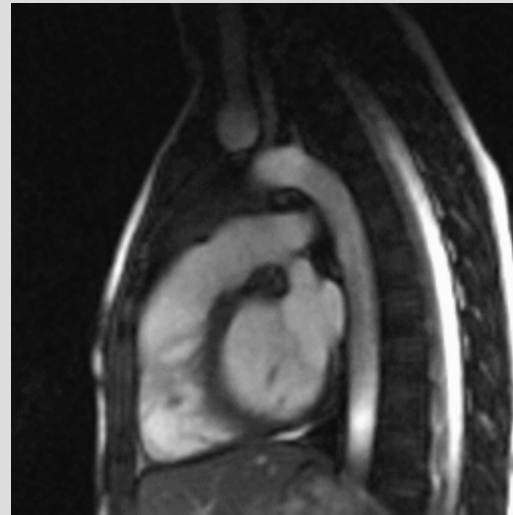
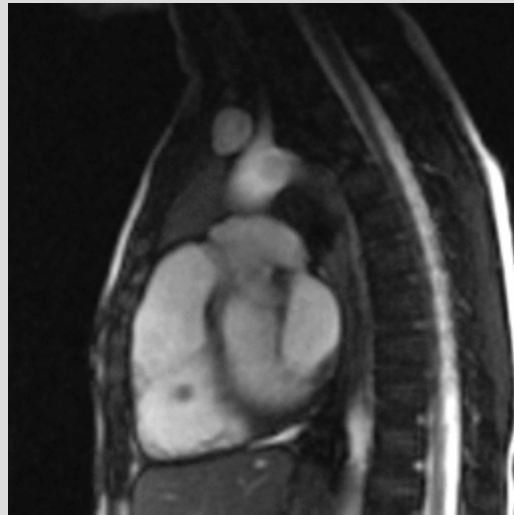
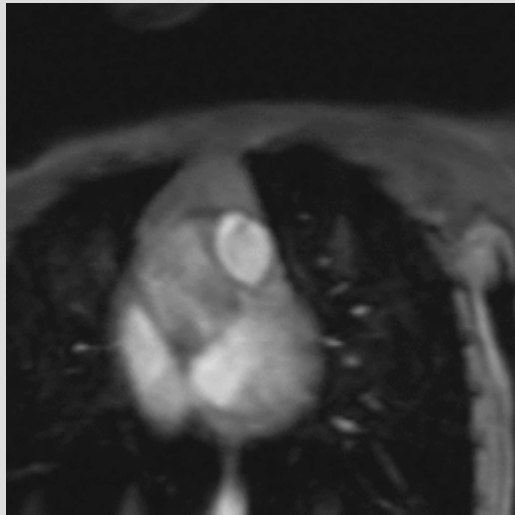




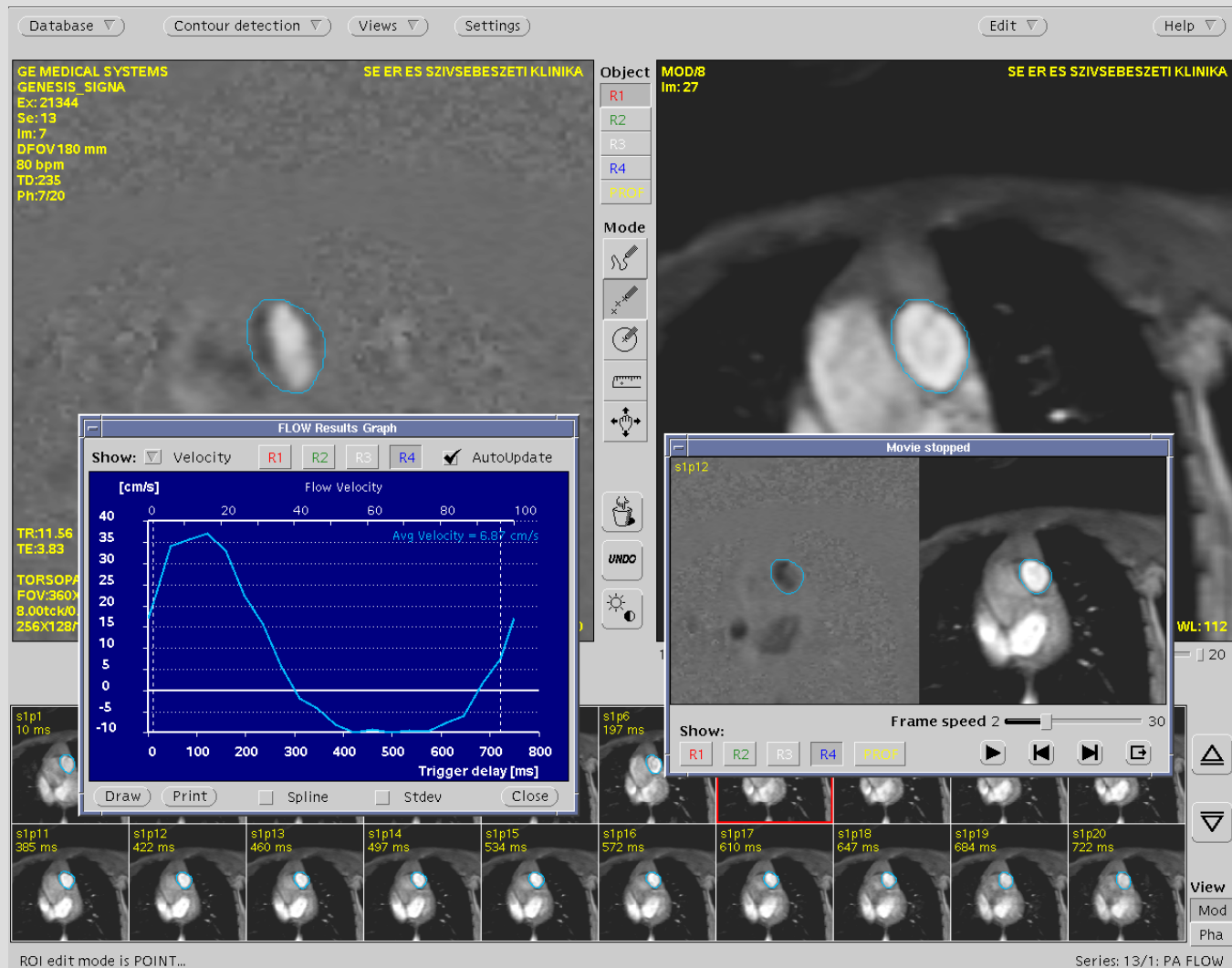
# FIV st.p.op.



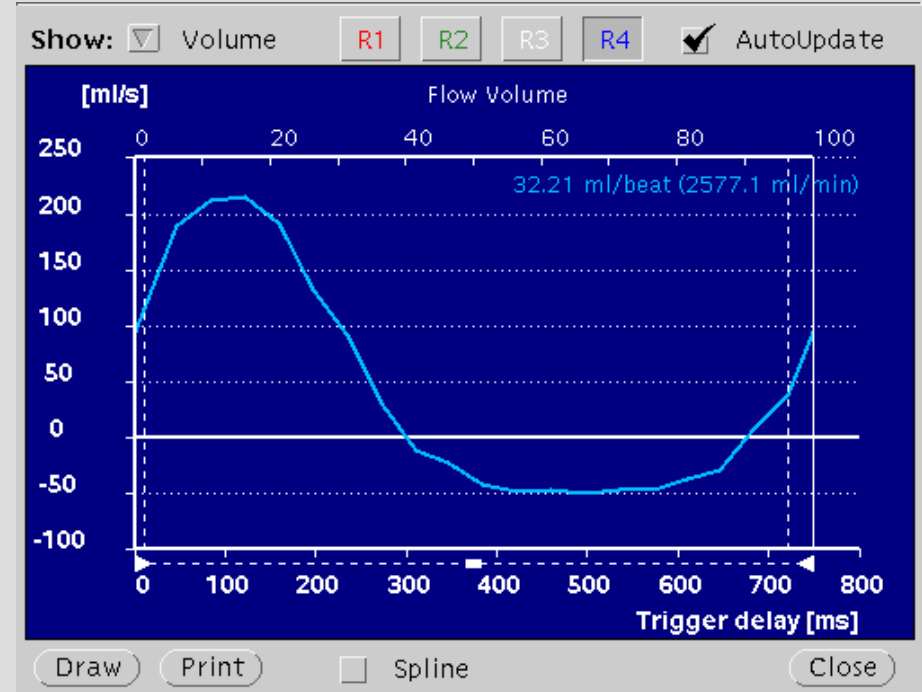
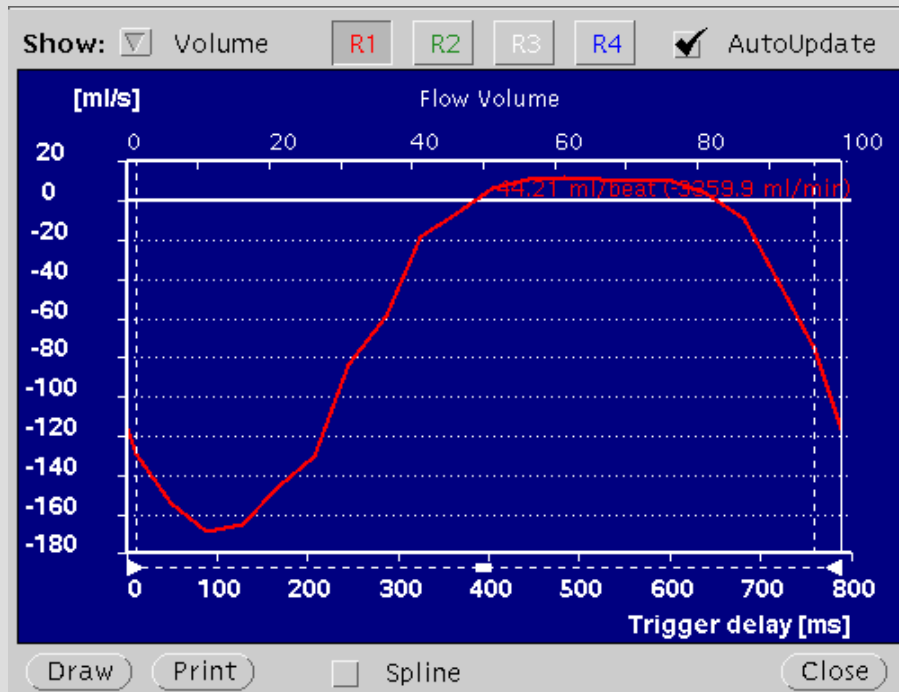
# RVOT FIESTA



# Flow evaluation



# Flow measurements



# Functional evaluation

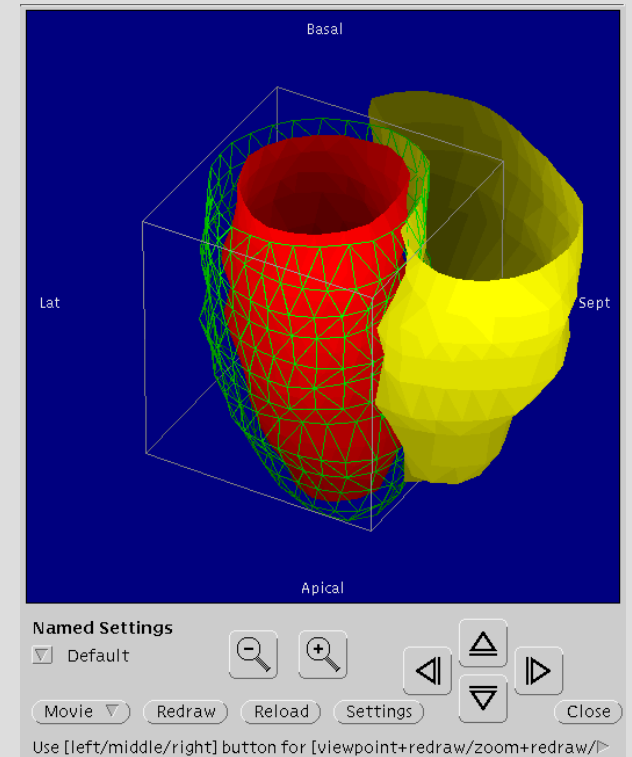
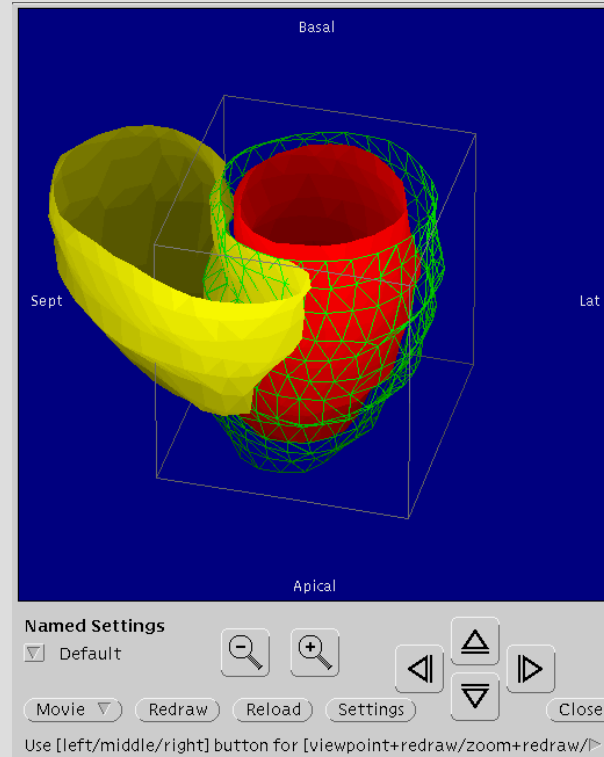
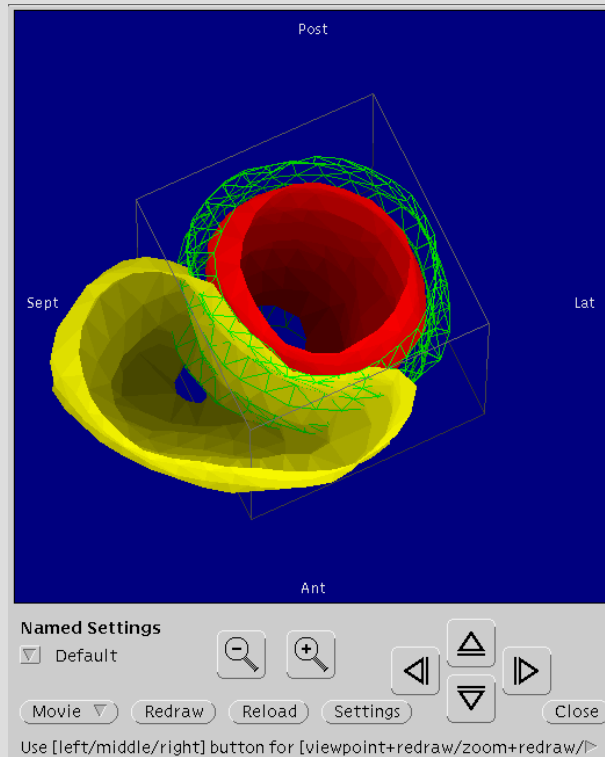
The screenshot displays a medical software interface for cardiac MRI functional evaluation. The interface is divided into several sections:

- Database / Contour detection / Views / Settings:** Navigation and configuration options at the top.
- Slices:** A grid showing 20 slices (1-20) and 20 phases (1-20). The grid is color-coded, with slices 1-10 in pink and 11-20 in grey. Phases 5, 10, and 15 are highlighted in green. A red box highlights slice 10, phase 20.
- Study View:** A grid of 8 small image thumbnails showing different slices and phases, labeled with IDs like s10p9, s10p10, etc.
- Movie:** A window showing a sequence of frames (s10p20) with a play button and other controls.
- Main Image Window:** A large image showing a cross-section of the heart with contours (yellow, green, red) overlaid. Technical data is displayed in the top right corner.

**Technical Data:**

- GE MEDICAL SYSTEMS
- GENESIS\_SIGNA
- SE ER ES SZIVSEBESZETI KLINIKA
- Ex: 24128
- Se: 17
- Im: 200
- SP: 12.98
- DFOV 180 mm
- 73 bpm
- TD: 790
- SI: 10/14
- PR: 20/20
- 20060724
- 171257
- Mag: 2.00
- WW: 950 WL: 351
- Contrast: 55 Brightness: 55

# Functional evaluation



# Thank you for your attention!

